



STROKE & COVID19

Cases from the Frontlines

Dr. Bay Leslie- Mazwi, Massachusetts General Hospital

Dr. Steven Feske, Brigham and Women's Hospital

Dr. Brett Cucchiara, The Hospital of the University of Pennsylvania





BRIGHAM AND
WOMEN'S HOSPITAL



COVID-19 and Stroke AHA Webinar



*Steven Feske, M.D.
Chief, Stroke Division
Brigham and Women's Hospital*

May 21, 2020

Disclosures

Drs. Cucchiara, Feske, and Leslie-Mazwi have no relevant disclosures.

Case: COVID-19 and LVO

56-year-old woman with obesity.

Confirmed positive for COVID-19 and hospitalized for respiratory distress, not intubated.

6:00 PM - Report of mild left-sided weakness; NIHSS = 4. LSW > 4.5 hr earlier; no IV tPA given.

11:00 PM – CT ASPECTS = 10. CTA R M1 occlusion; transfer initiated.

5:00 AM – Arrival at receiving hospital; NIHSS = 14.

7:00 AM – CT ASPECTS = 8. Intubation after head CT.

8:57 AM – Groin puncture.

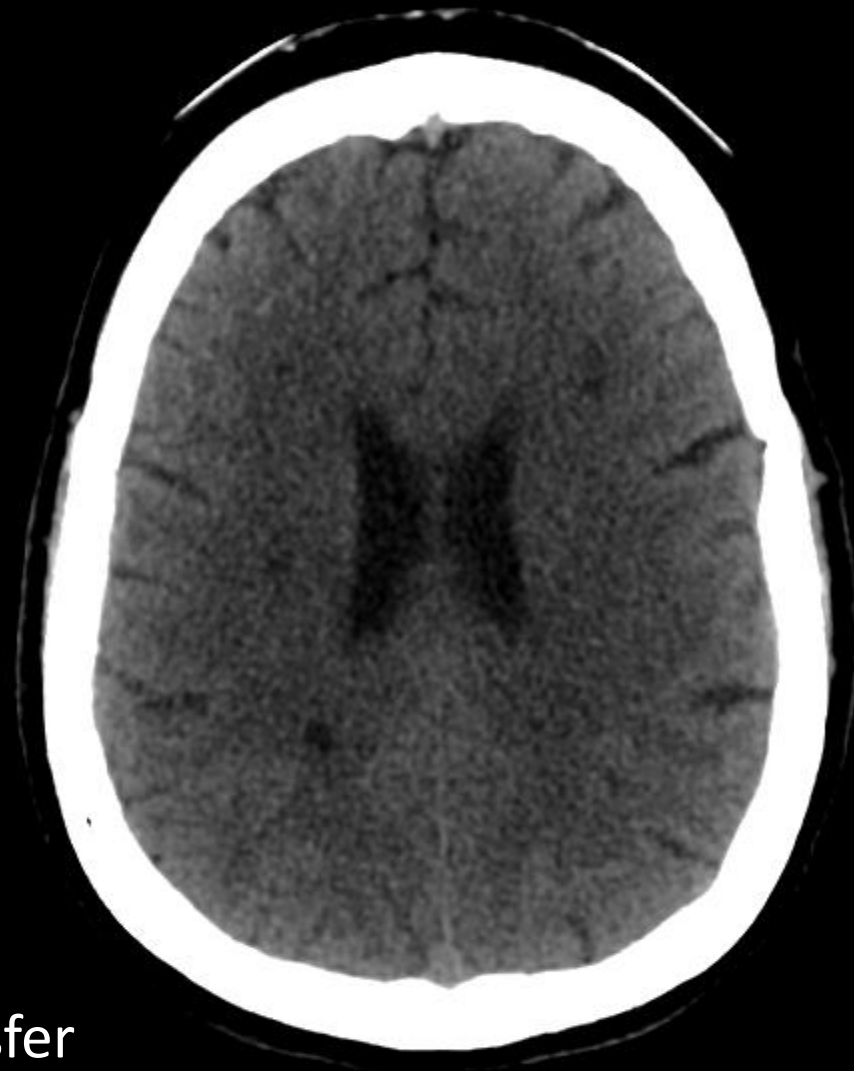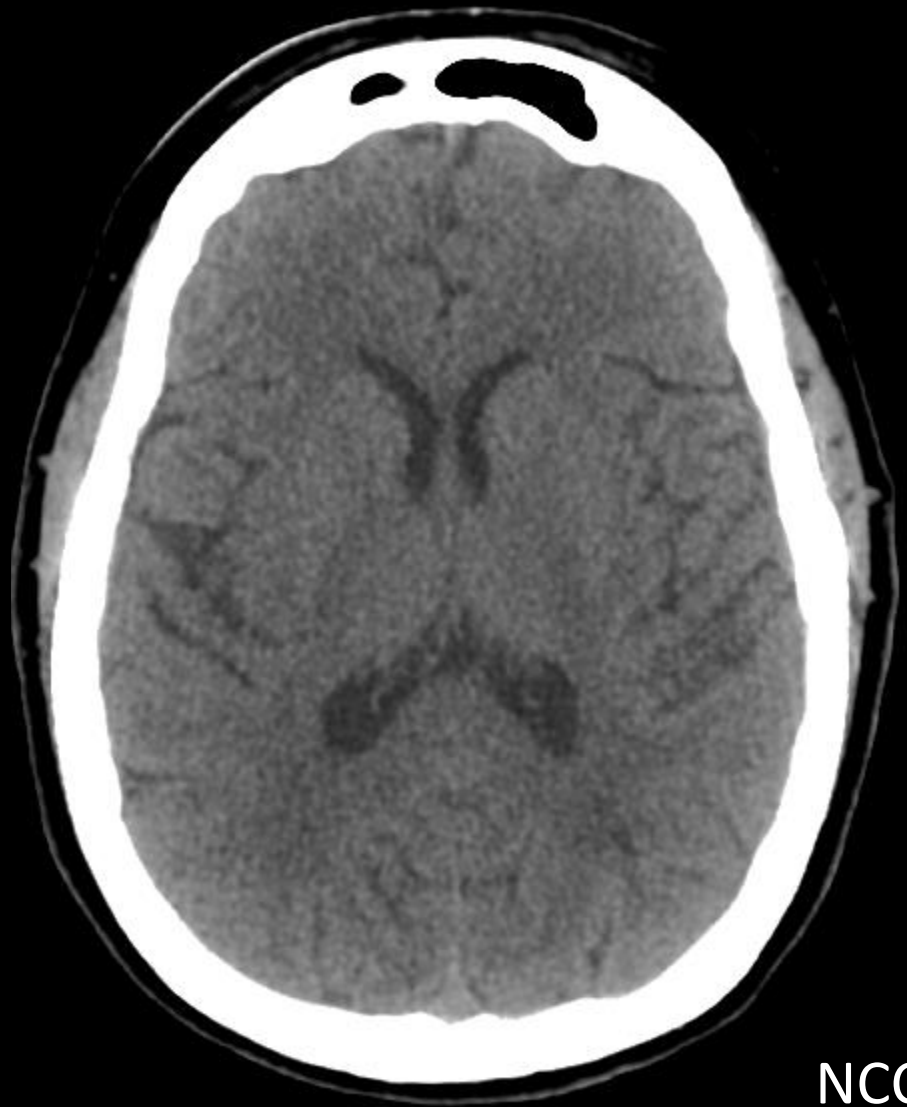9:07 AM – 1st pass with good reperfusion, TICl 2b. Second look within minutes shows re-occlusion.

9:16 AM – 2nd pass with good reperfusion, TICl 2b. Second look within minutes shows re-occlusion.

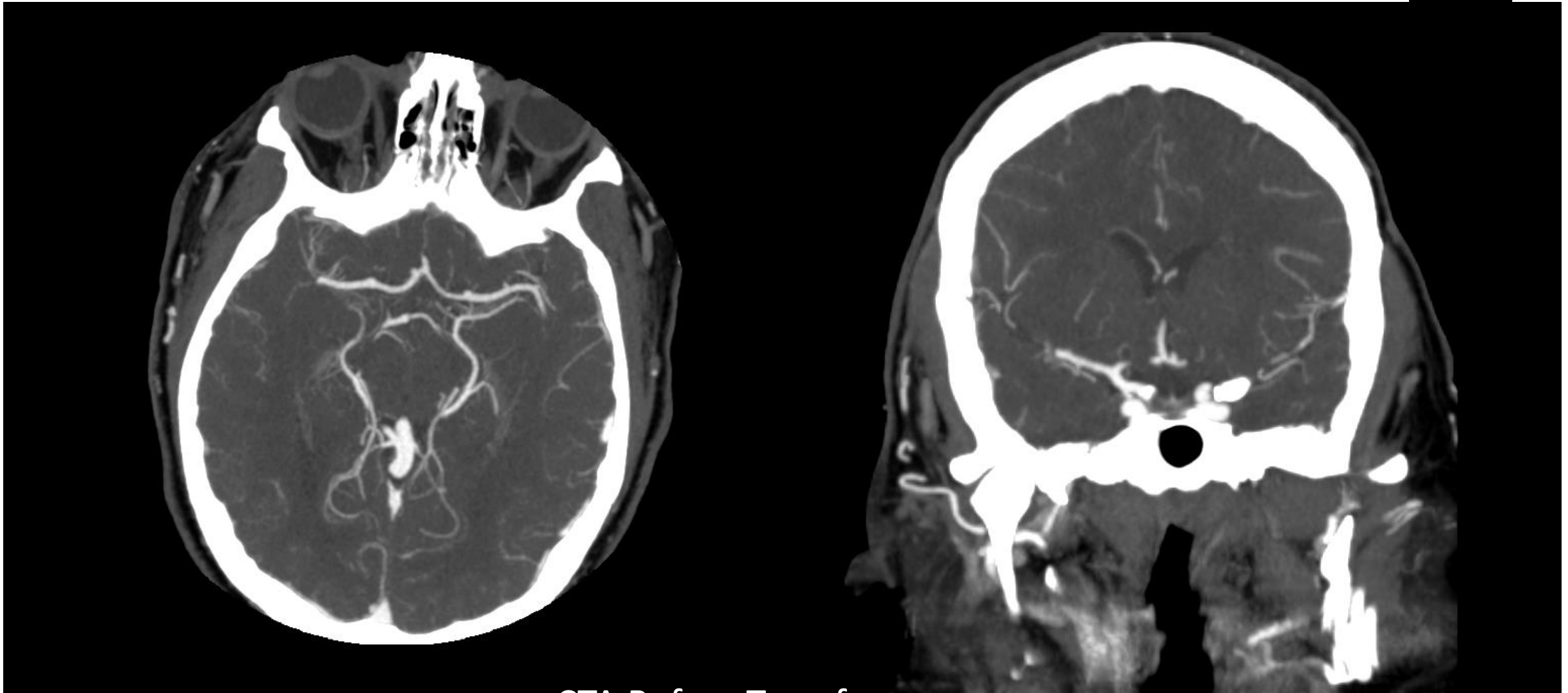
9:30 AM – 3rd pass with same result.

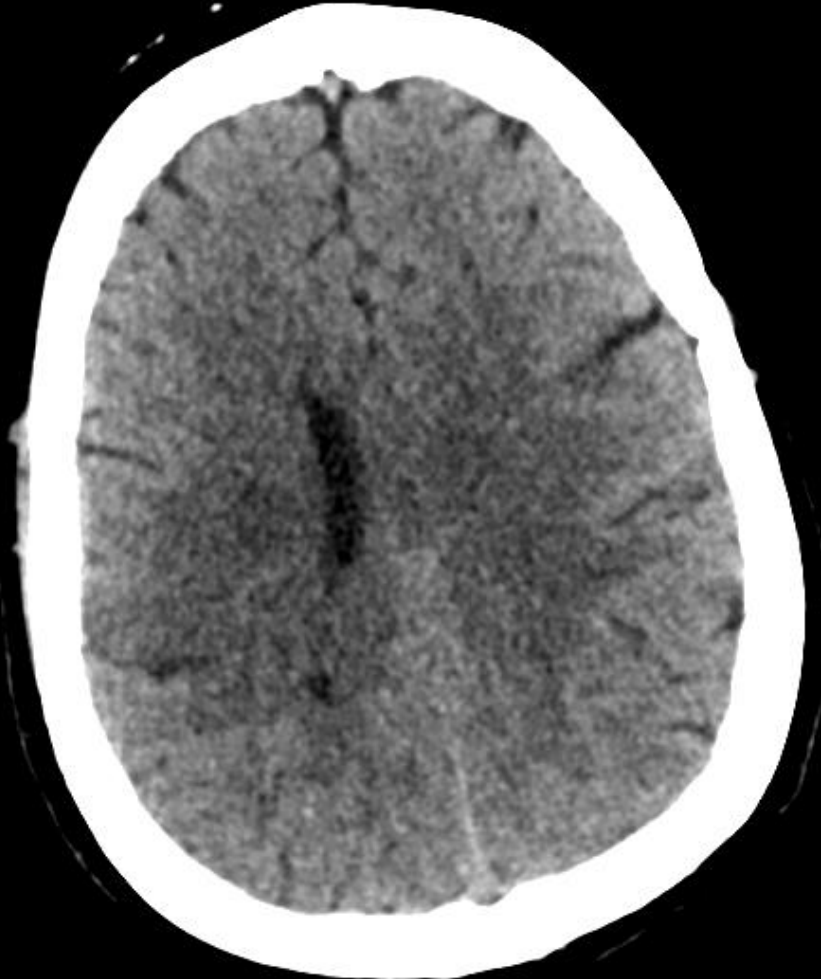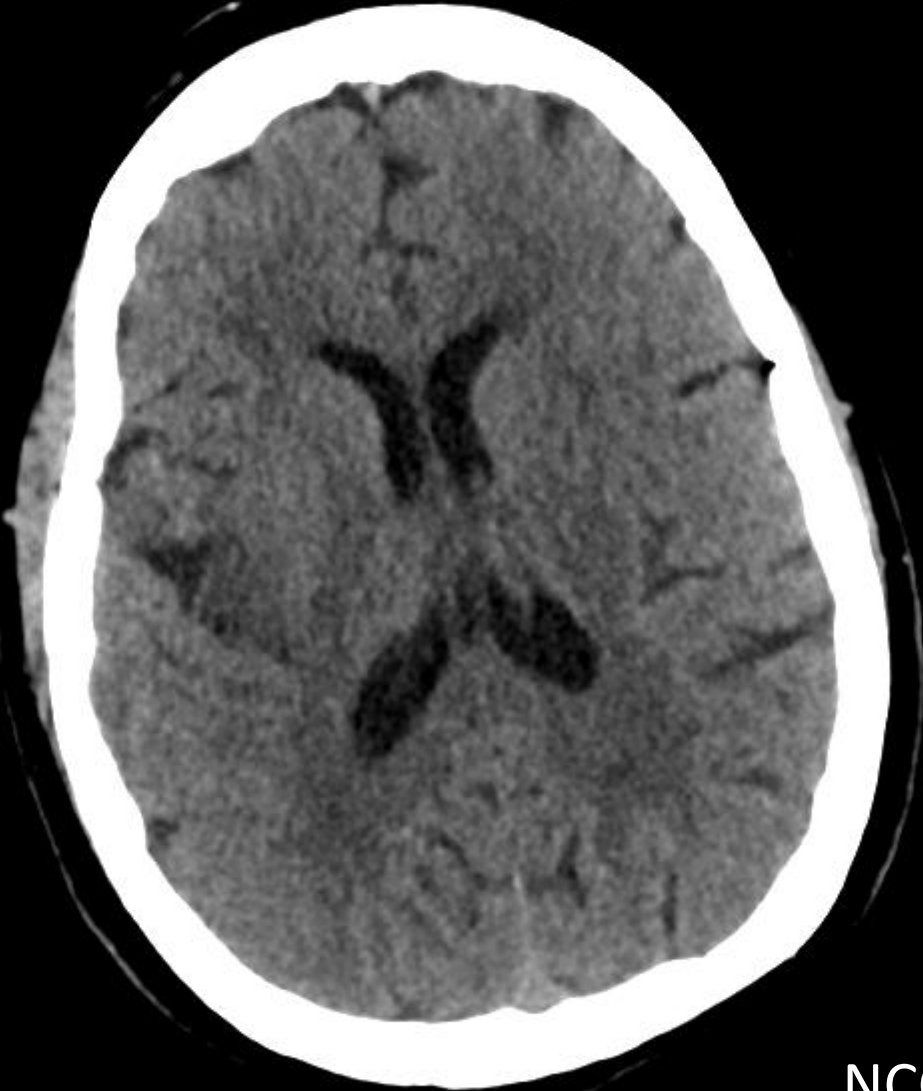9:45 AM – 4th pass with same result. Large clot removed.

POD 1 – Large right MCA territory infarct.

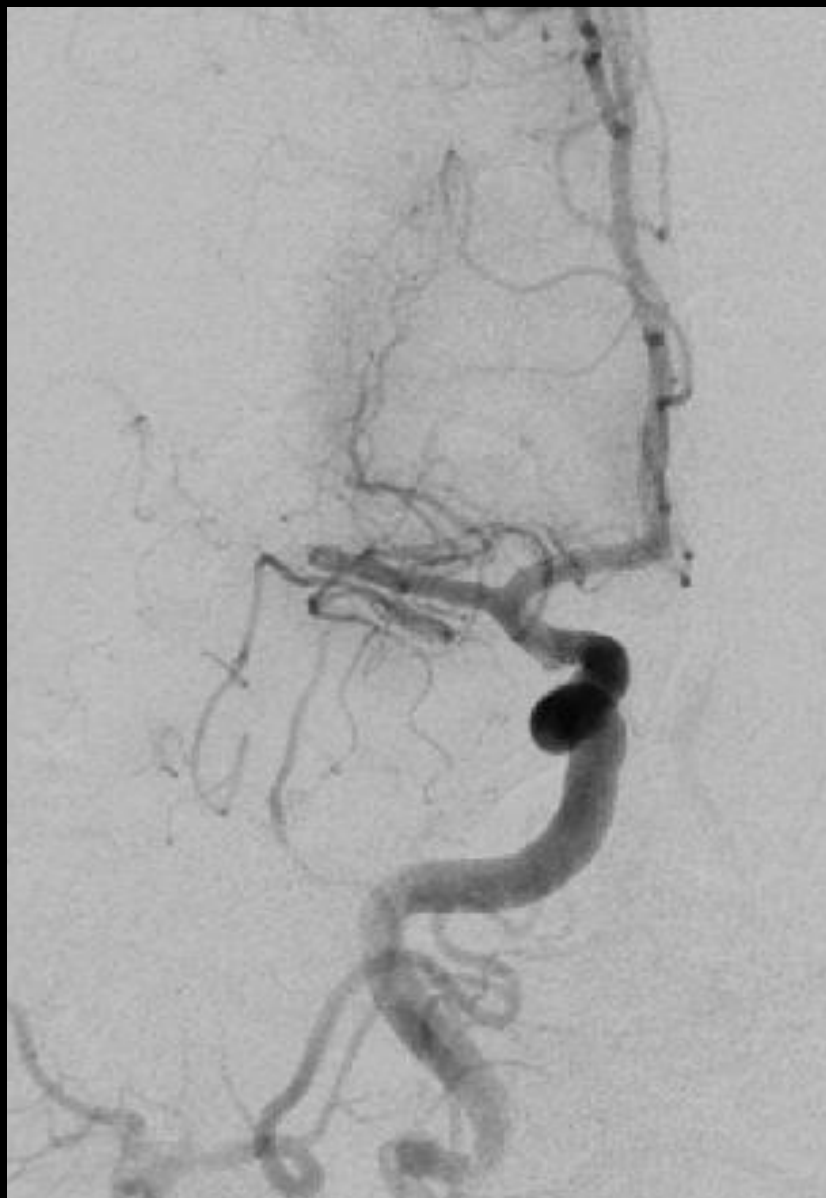

NCCT Before Transfer

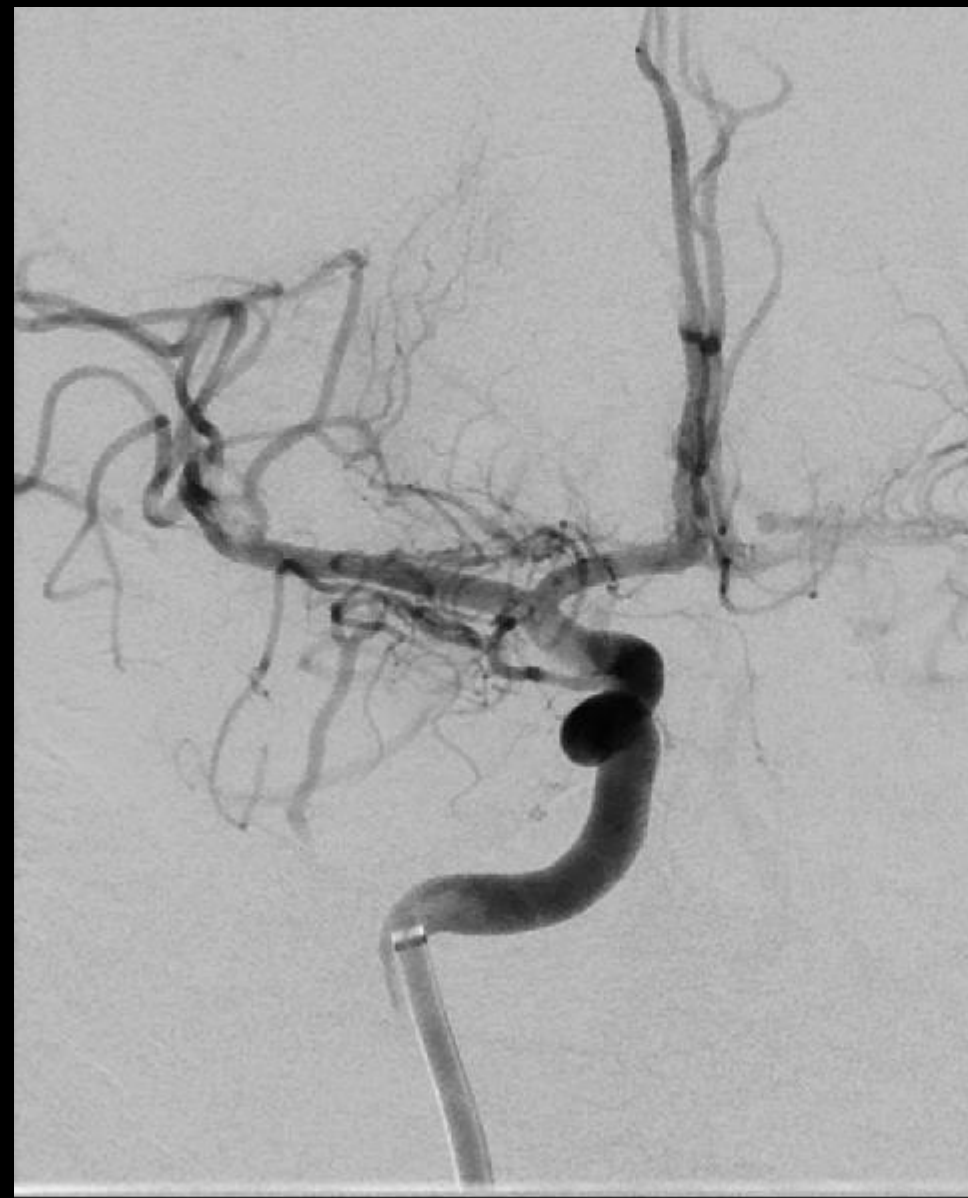




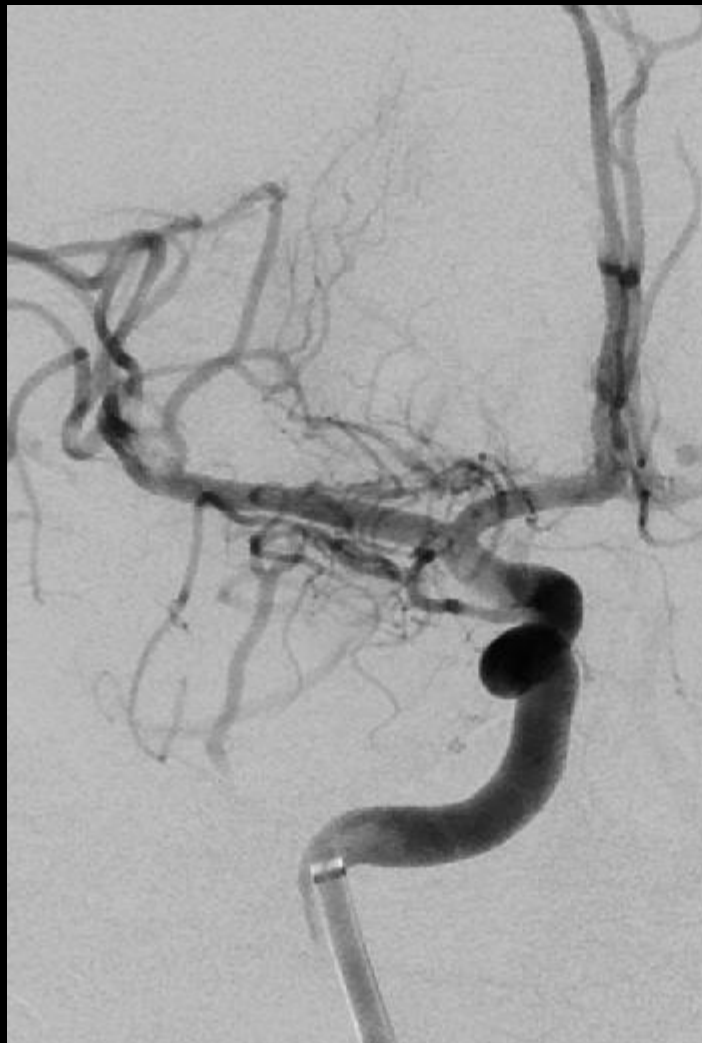NCCT Upon Arrival



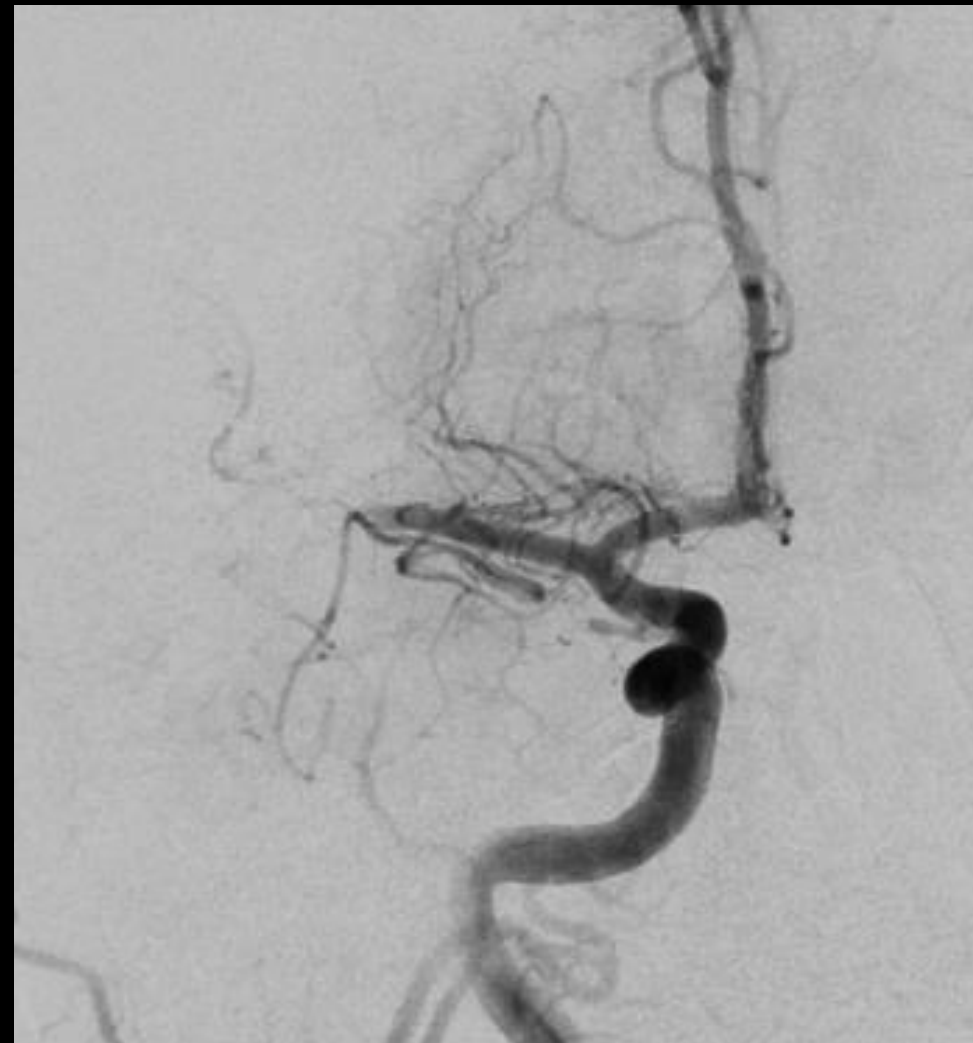Initial Angiogram



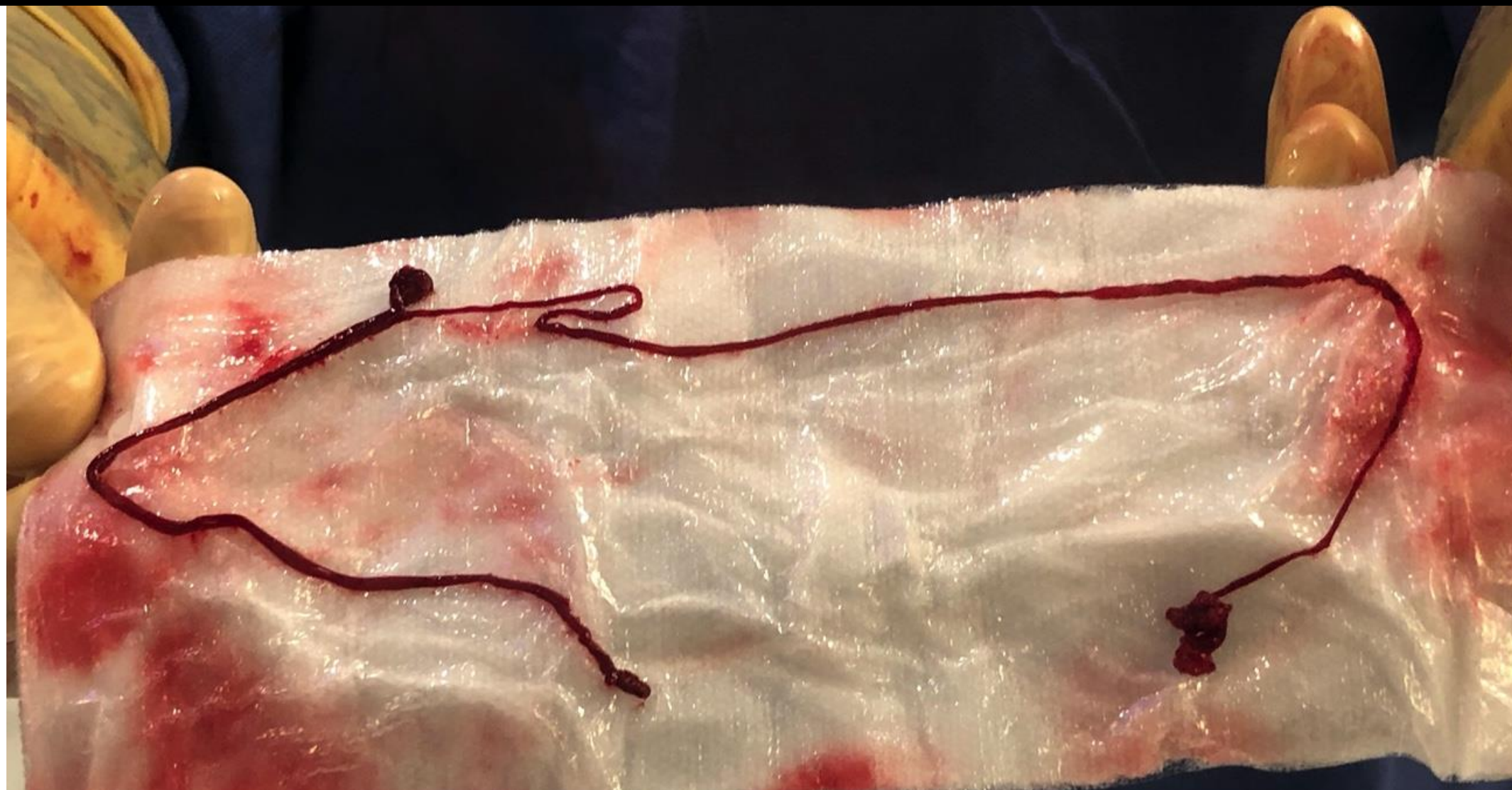After 1st Pass

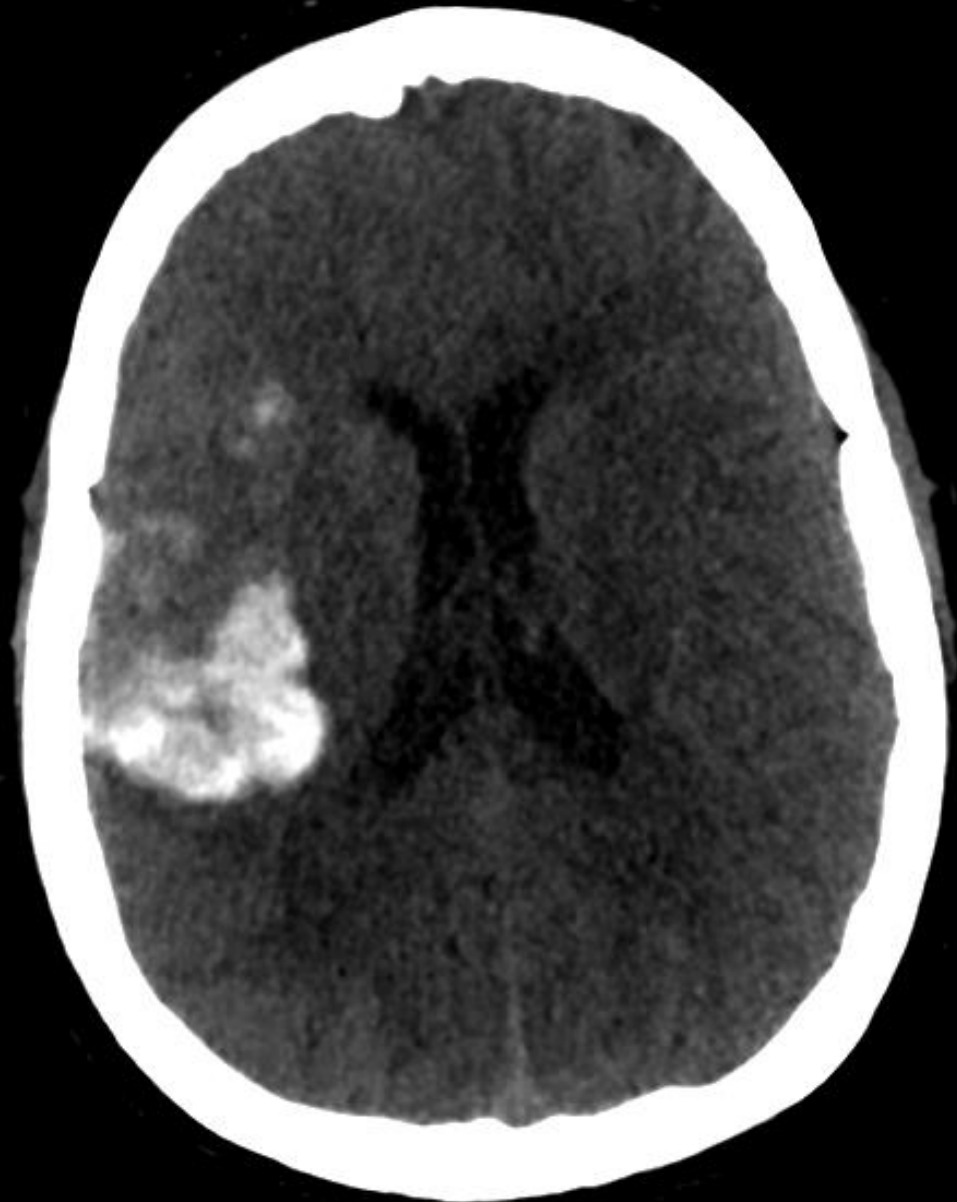

After 1st Pass

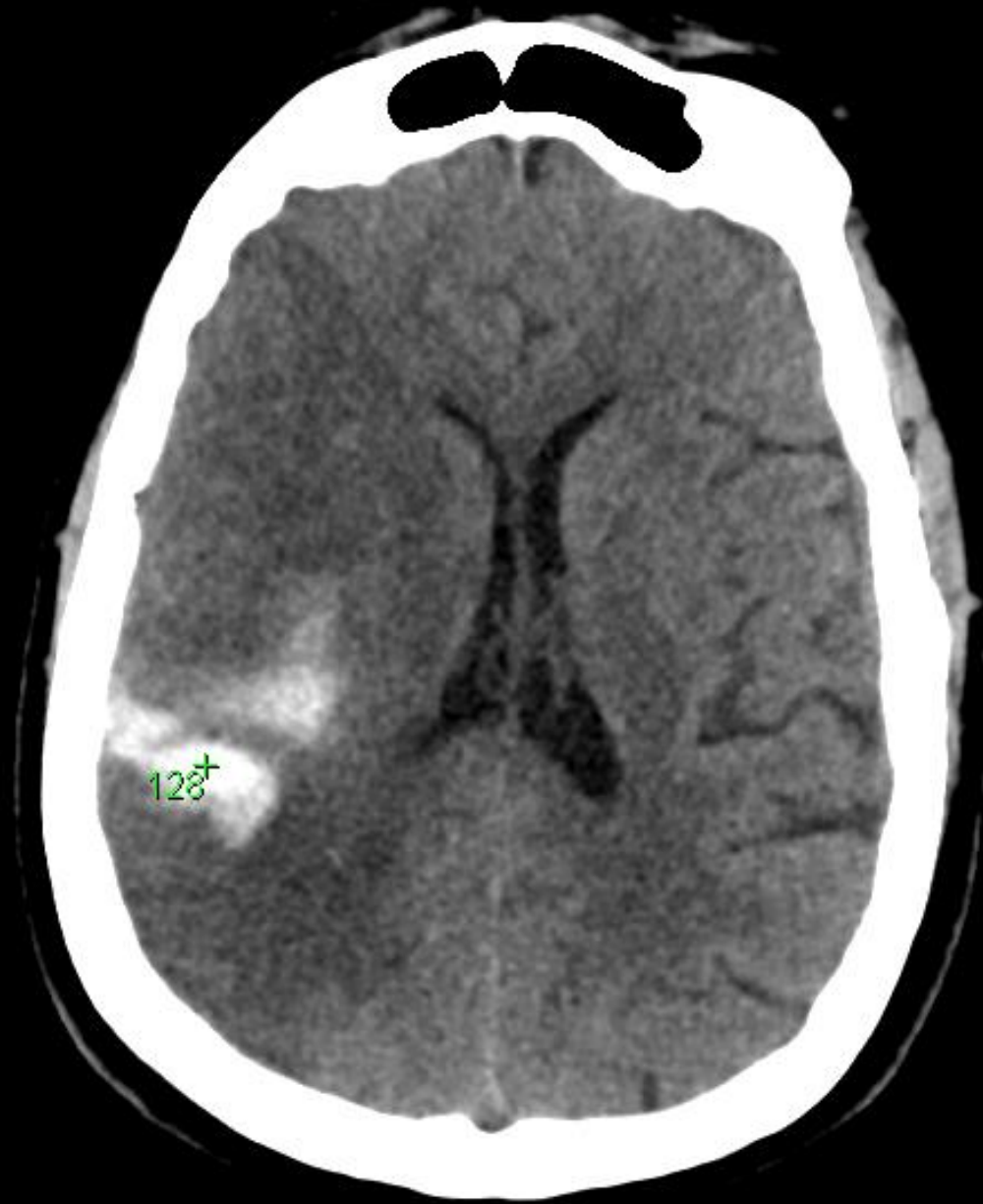


Re-occlusion





NCCT Post-proced



NCCT POD1

Considerations

Delays – What are the causes of delays? Can we shorten them?

- PPE donning and doffing, transport, imaging, intubation

Are patients hypercoagulable? Why? Should we treat with ACs?

- Klok Thromb Res 2020; Zhang NEJM 2020

Do patient with COVID-19 have increased risk of stroke? If so, what might be the mechanisms?

- Oxley TJ et al. NEJM 2020;382:e60.

CASE 1

24 YO M WITH NO PMH NOTED ABRUPT ONSET L LEG WEAKNESS IN THE EVENING

NEXT AM ON WAKING NOTED L ARM WEAKNESS AND DYSARTHRIA – CALLED 911

PARAMEDICS NOTED LOW GRADE FEVER; HE REPORTED SORE THROAT FOR PRIOR 2 WEEKS

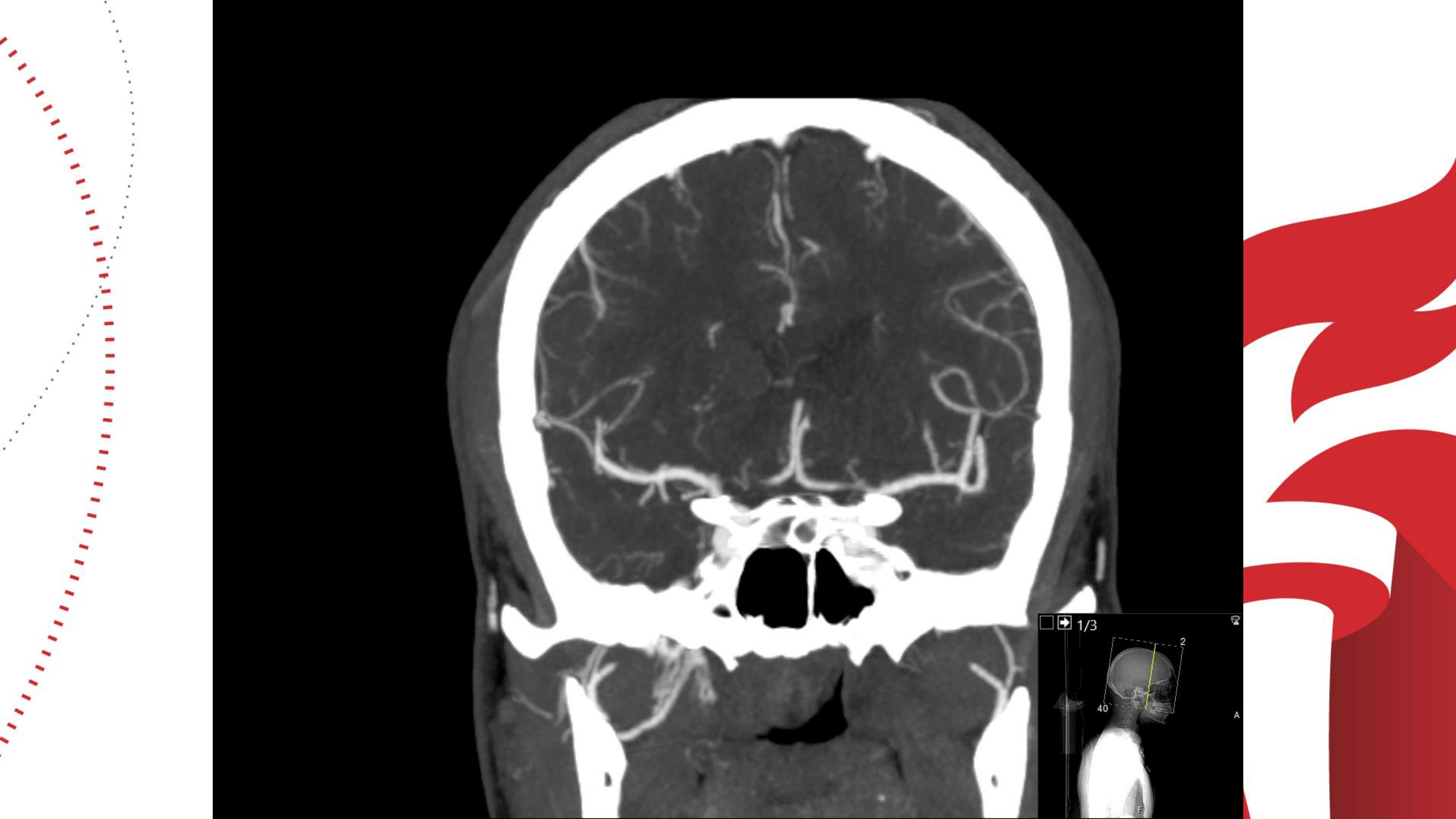
NO RESPIRATORY SYMPTOMS, VITALS NORMAL ON HOSPITAL ARRIVAL


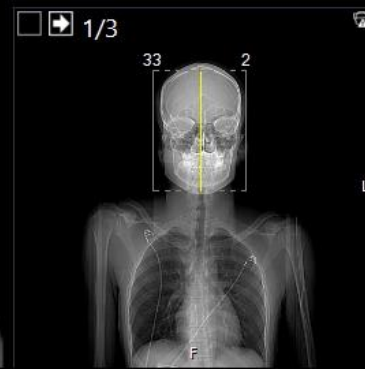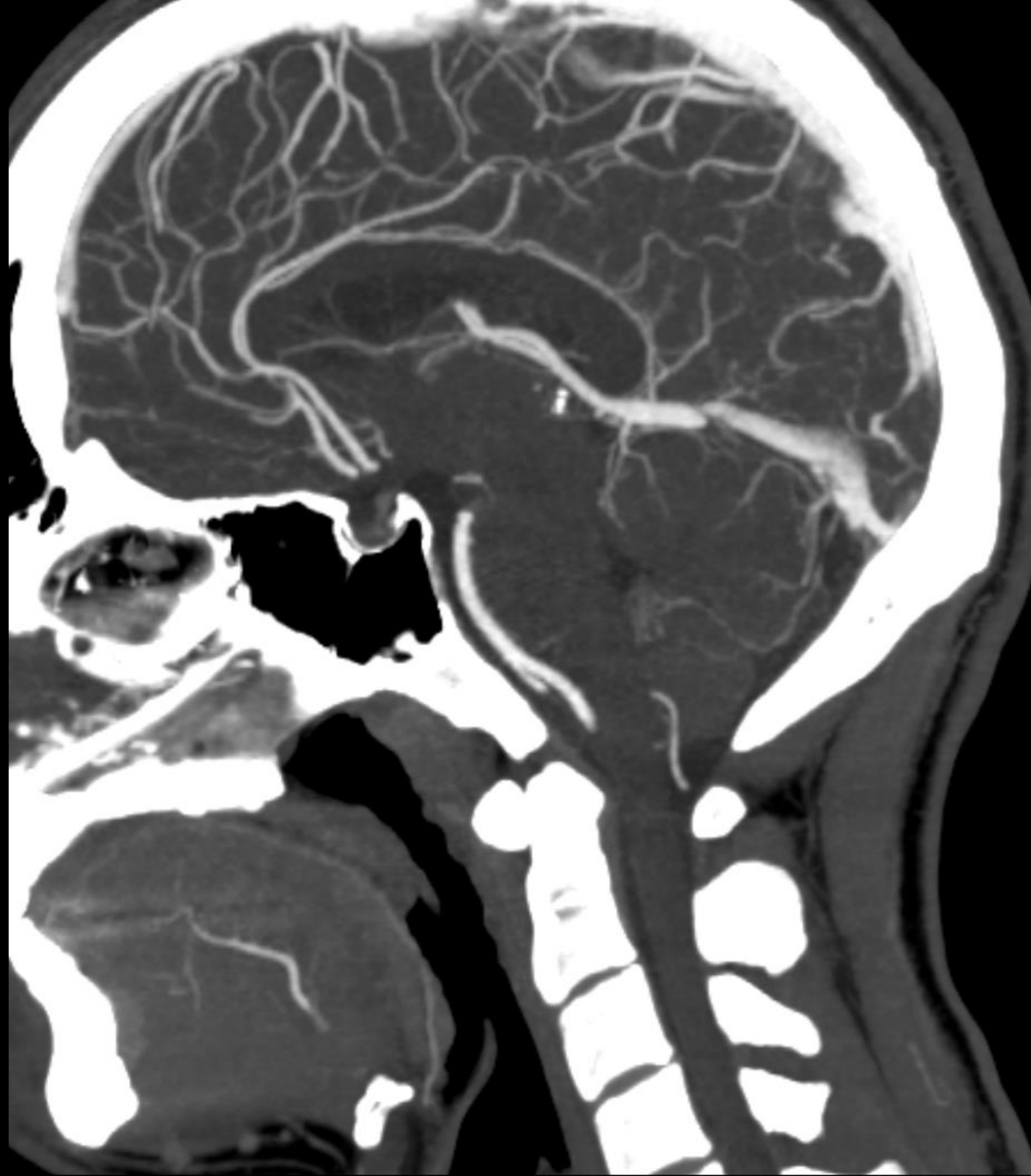
CASE 1


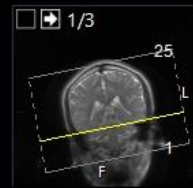
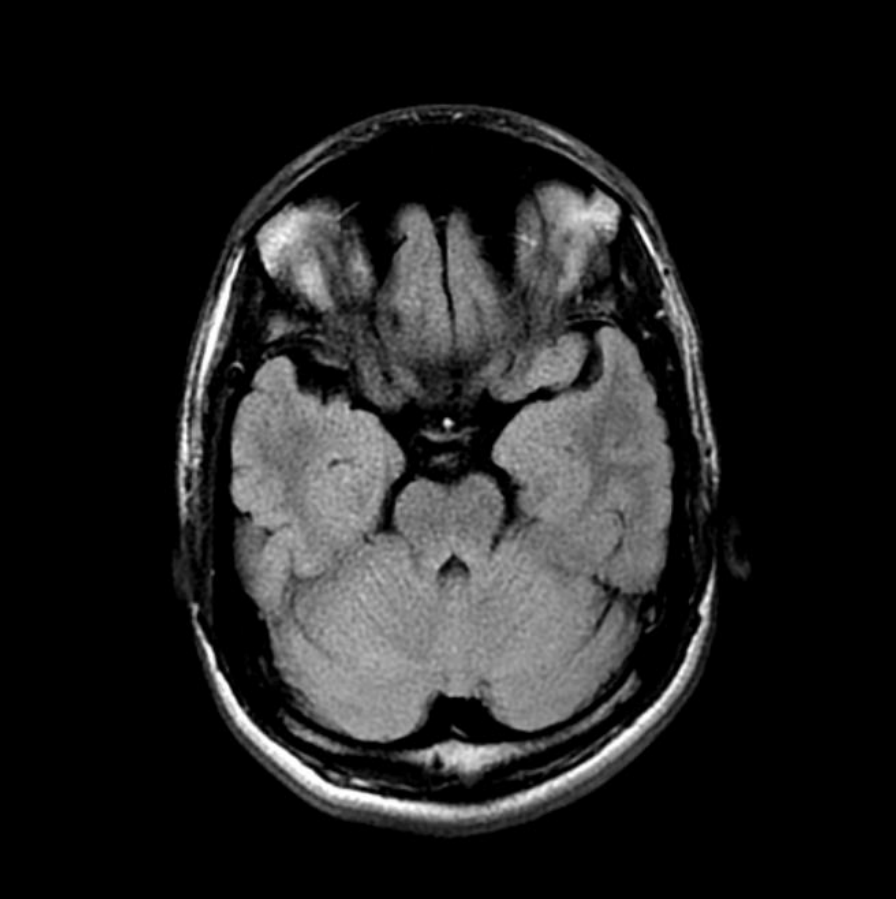
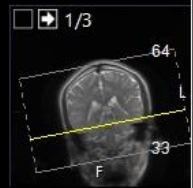
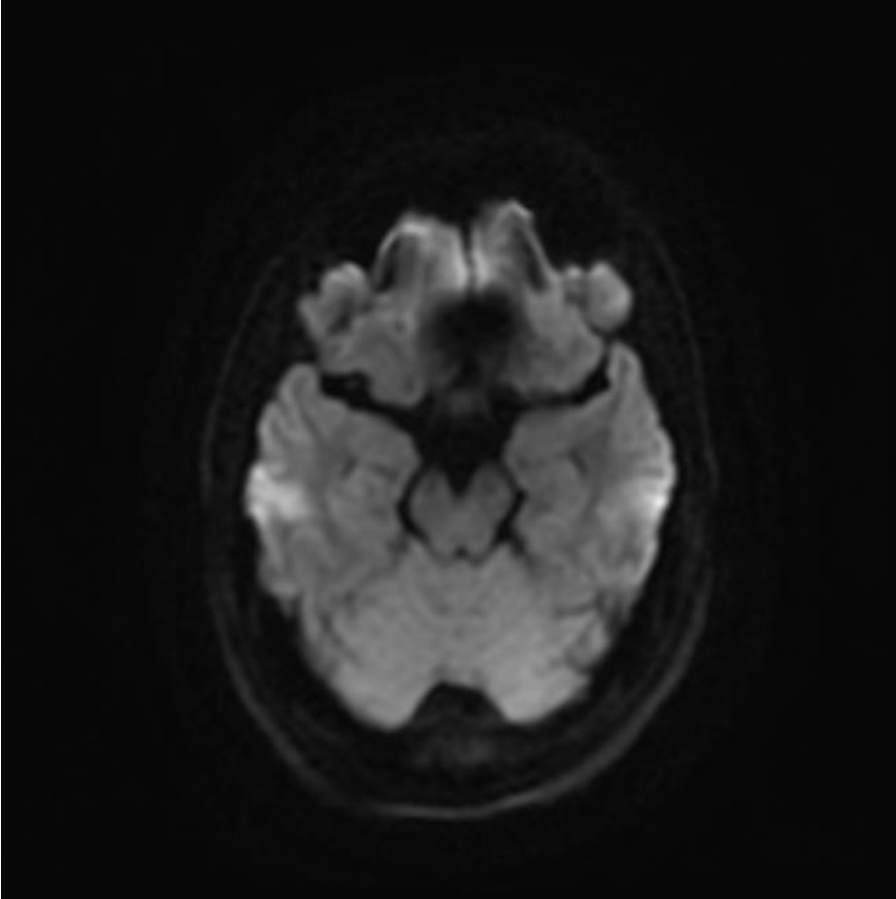
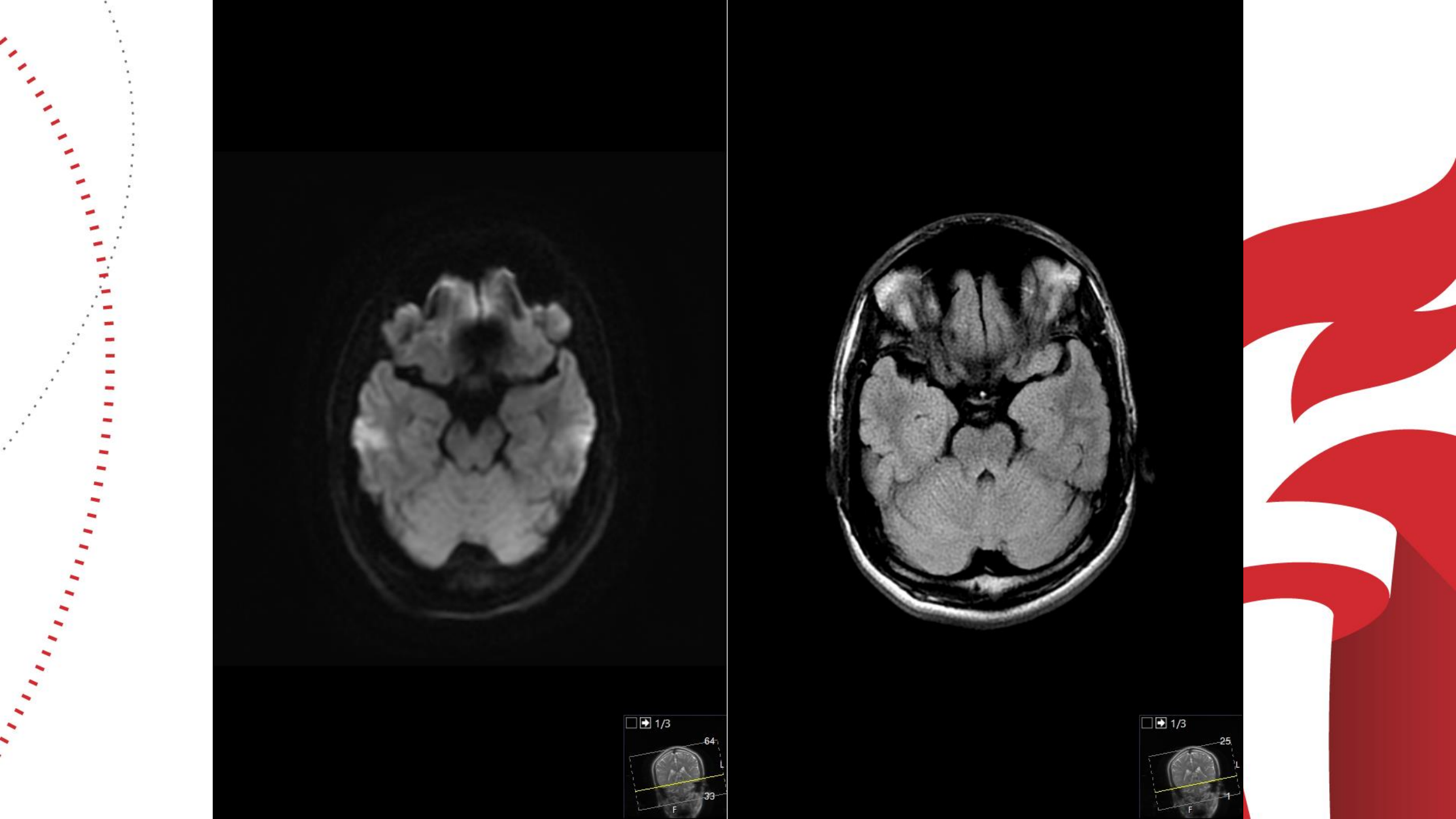
CTA AND MRI DONE

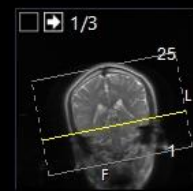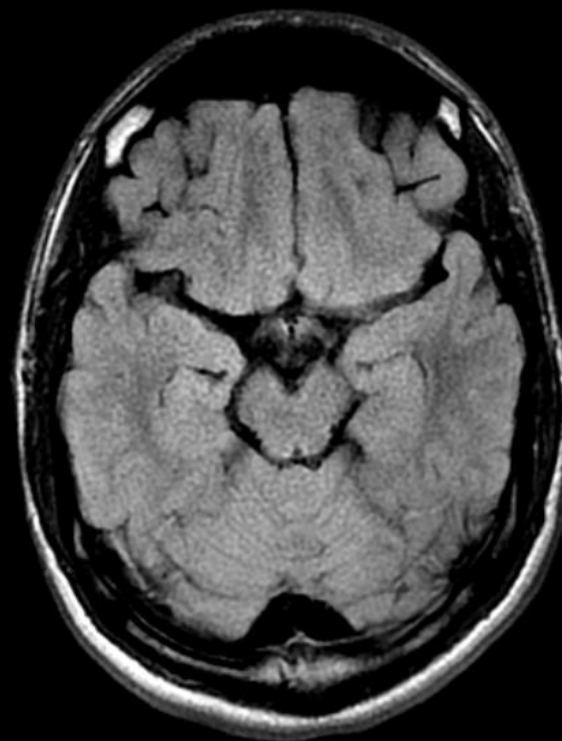
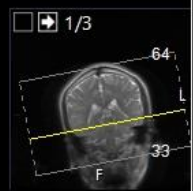
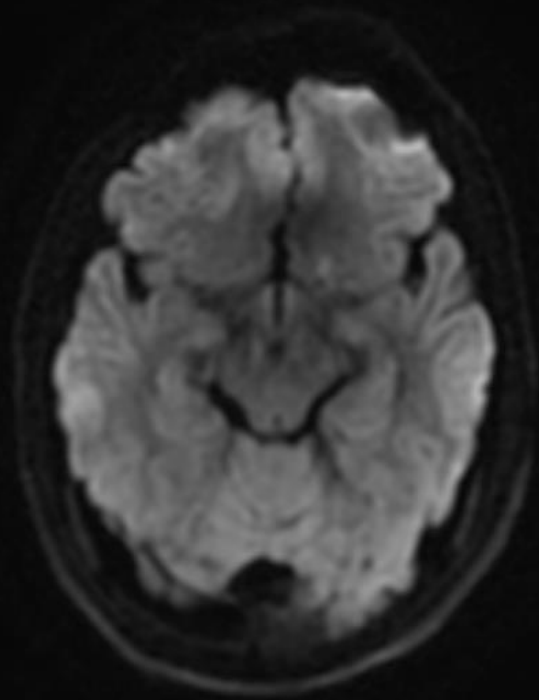
NO LVO OR VASCULAR ABNORMALITIES ON CTA

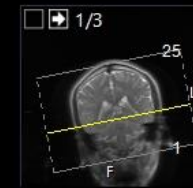
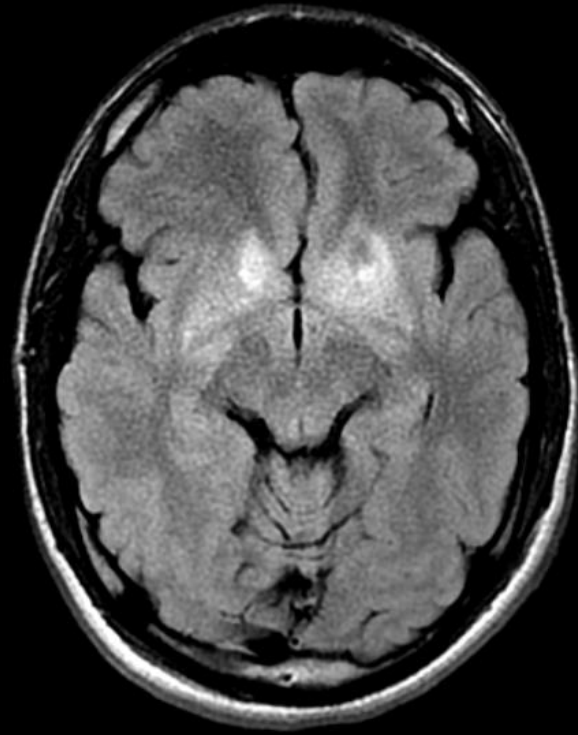
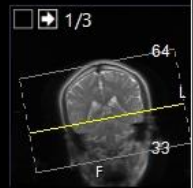
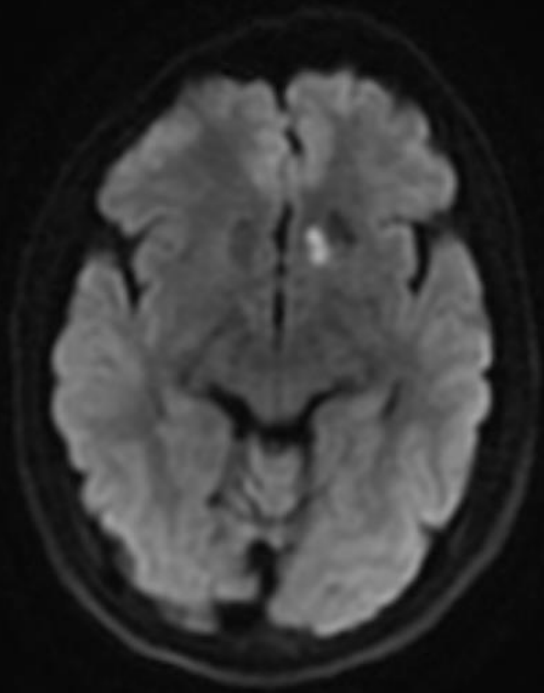
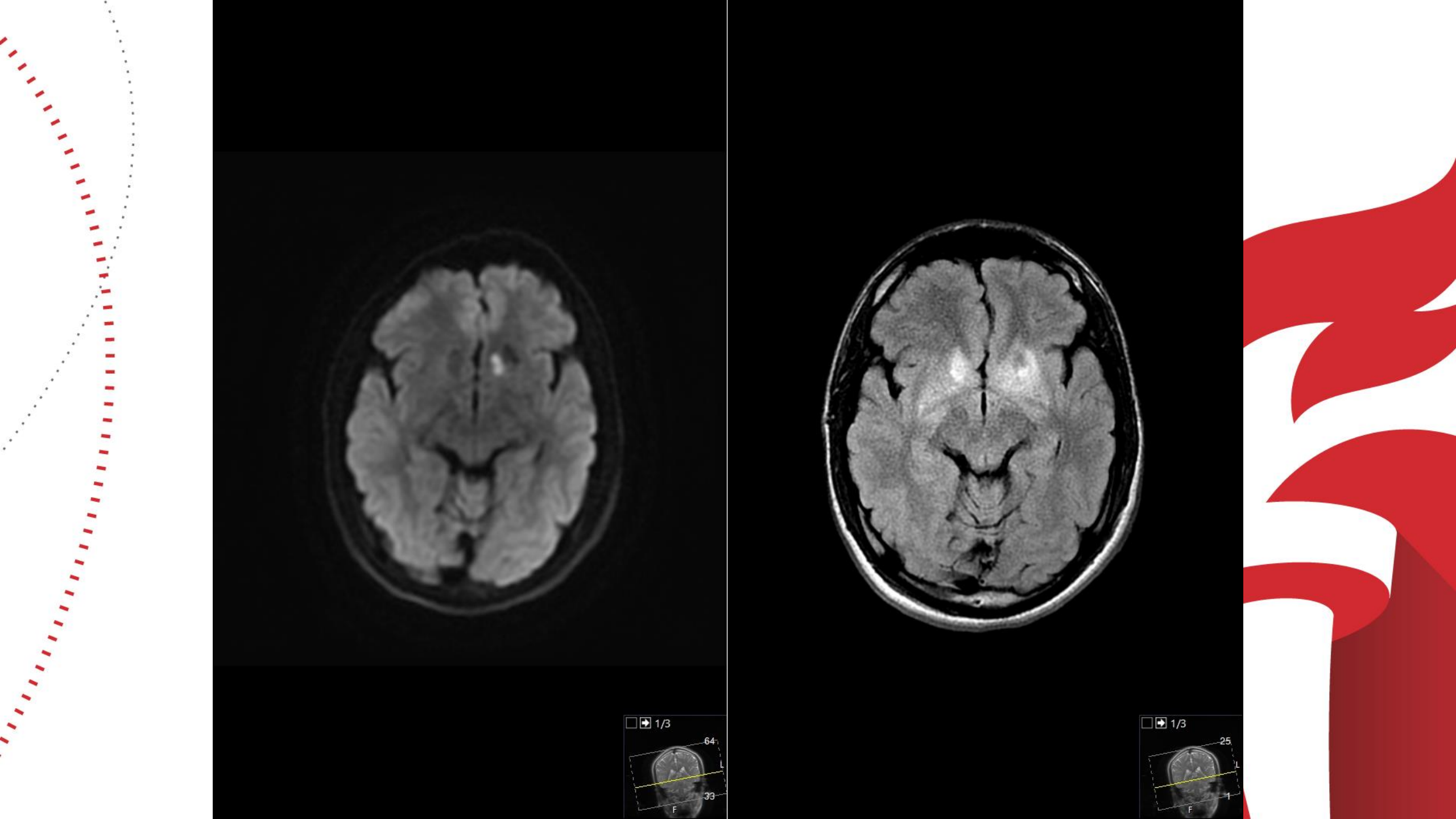
MRI ABNORMAL (SEE FILMS)

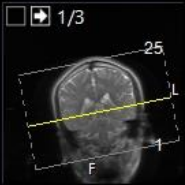
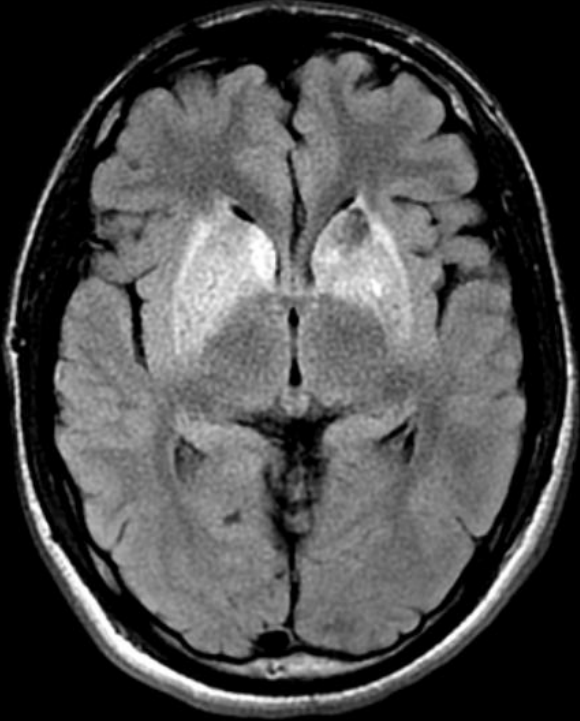
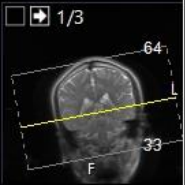
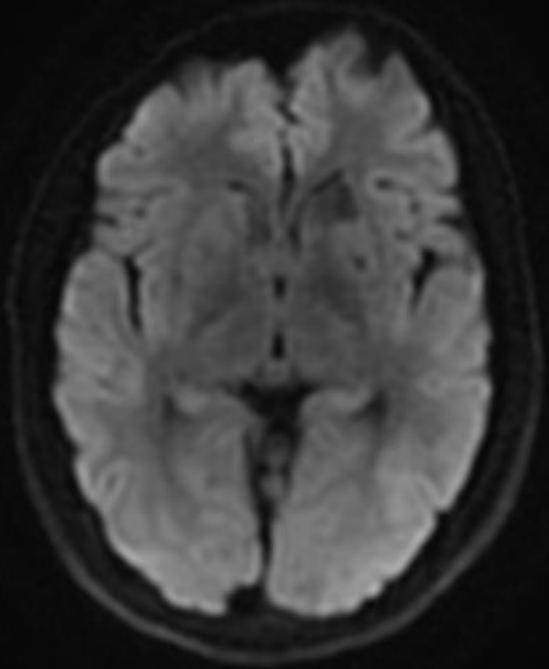
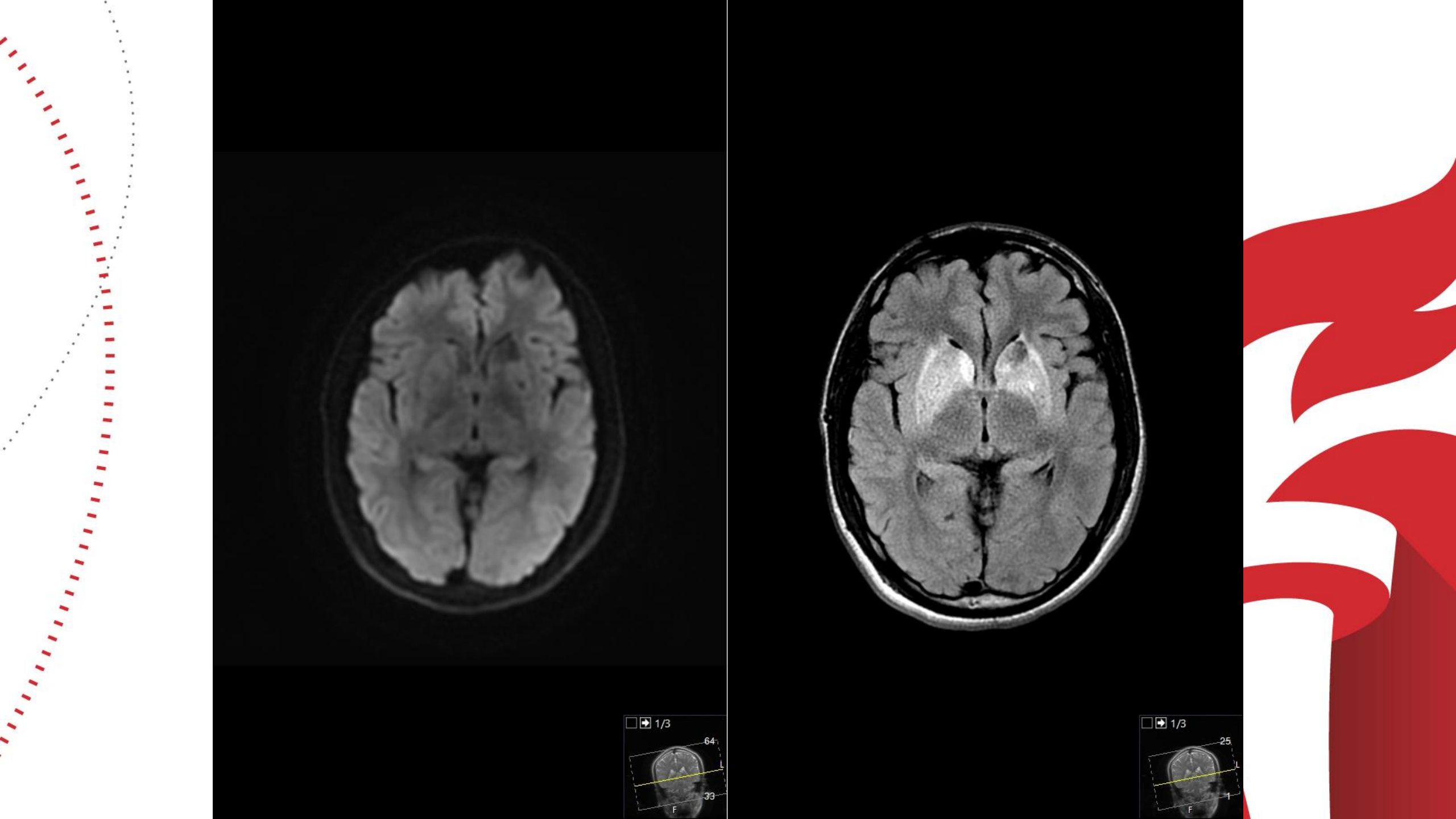


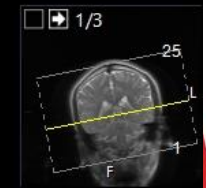
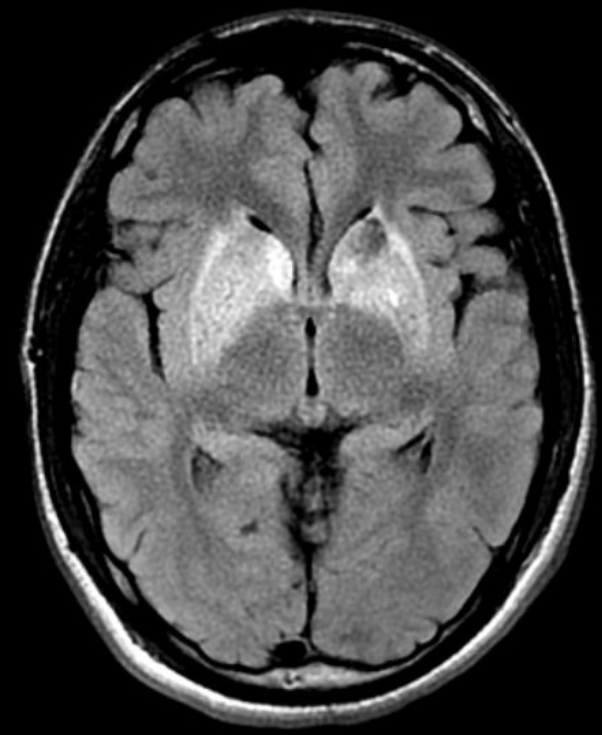
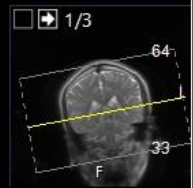
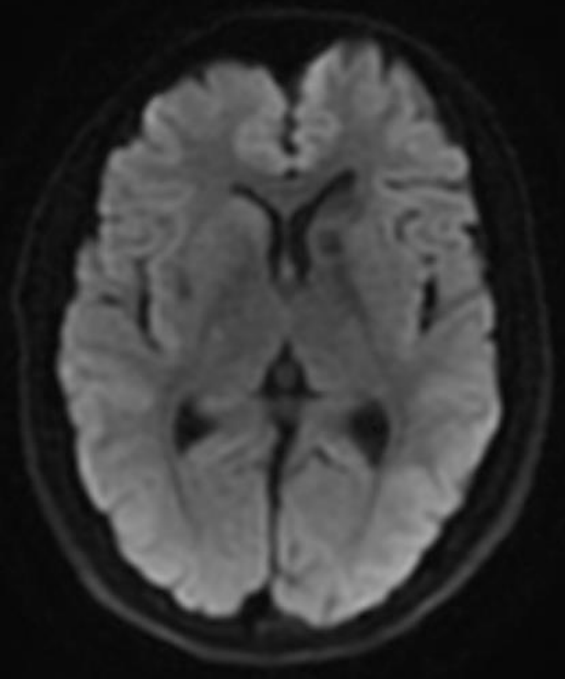
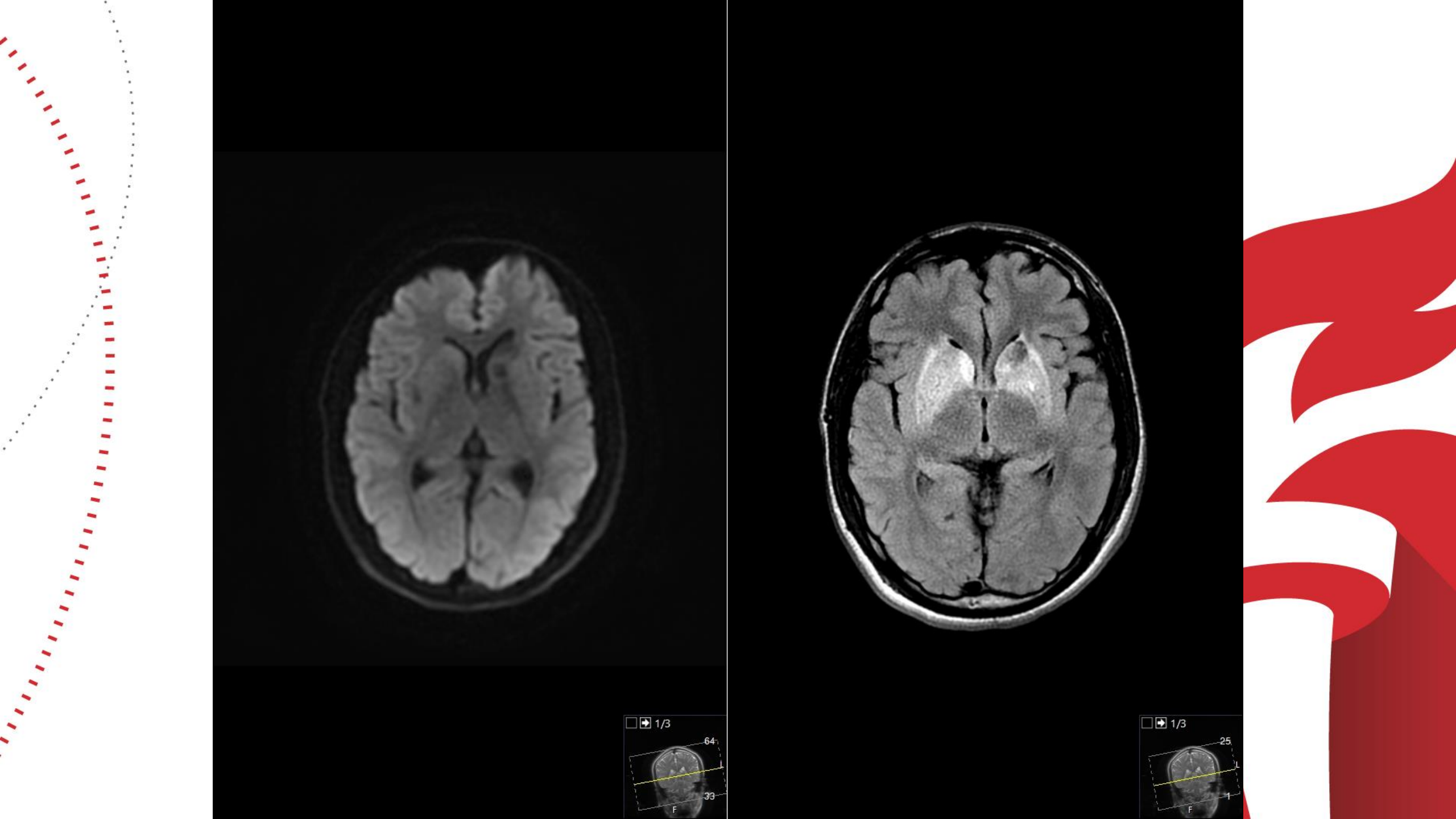


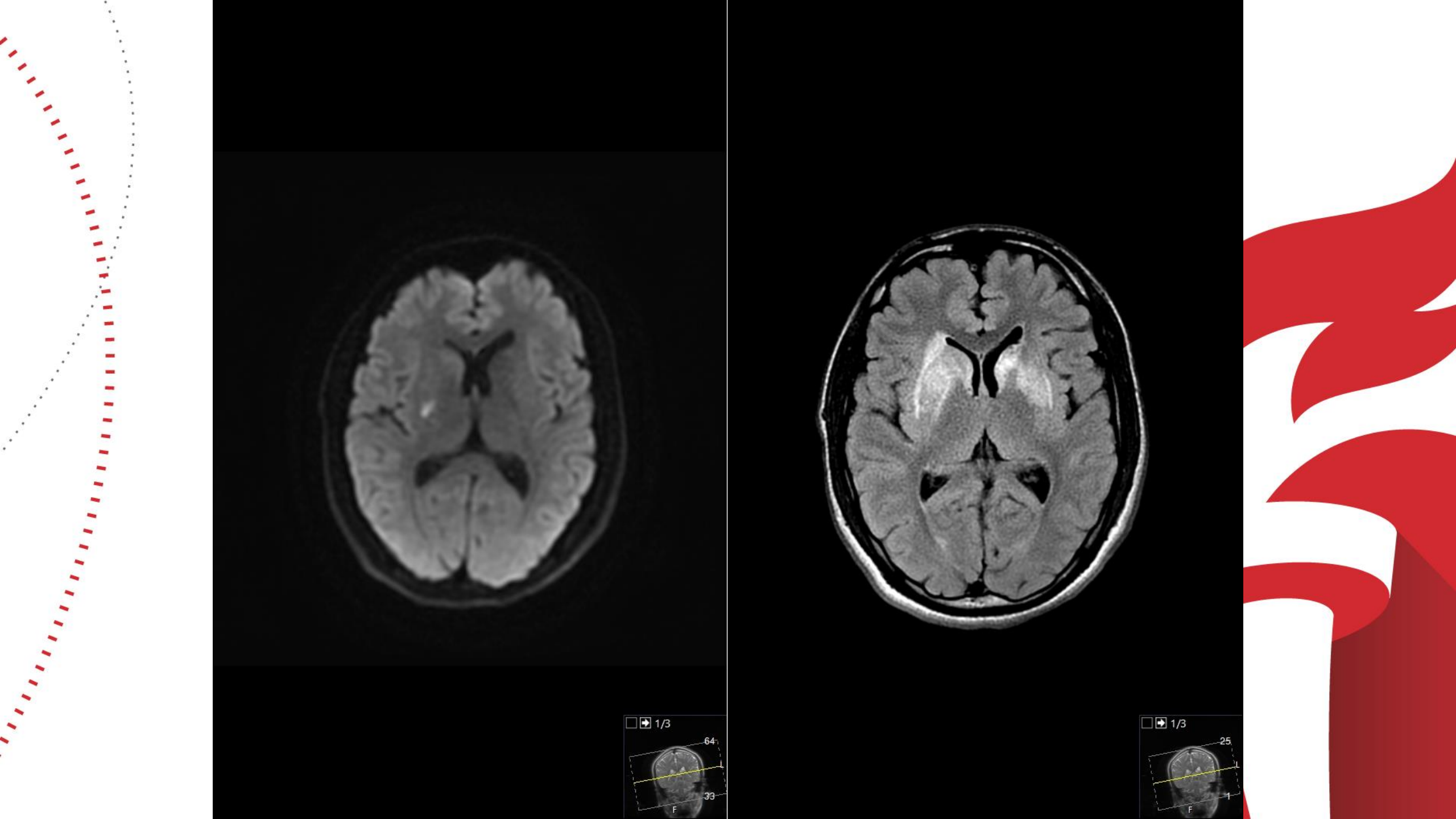
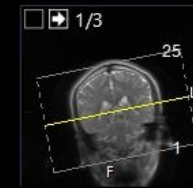
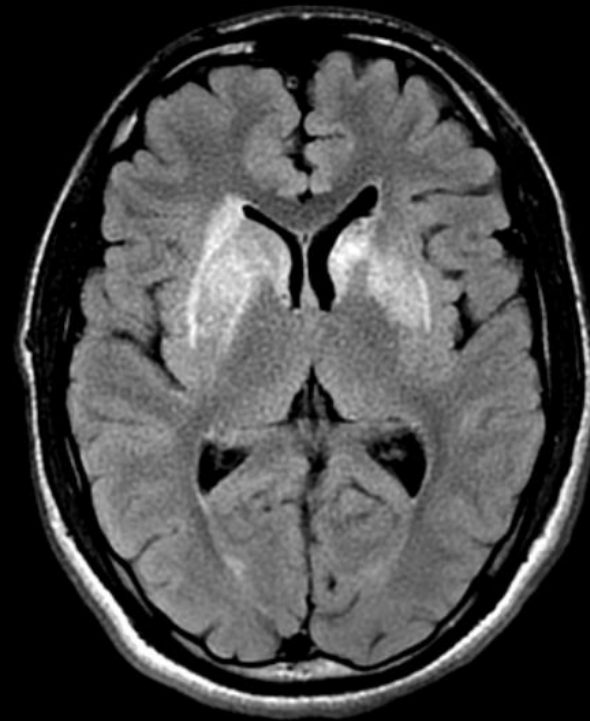
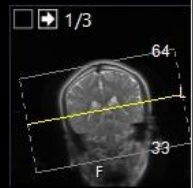
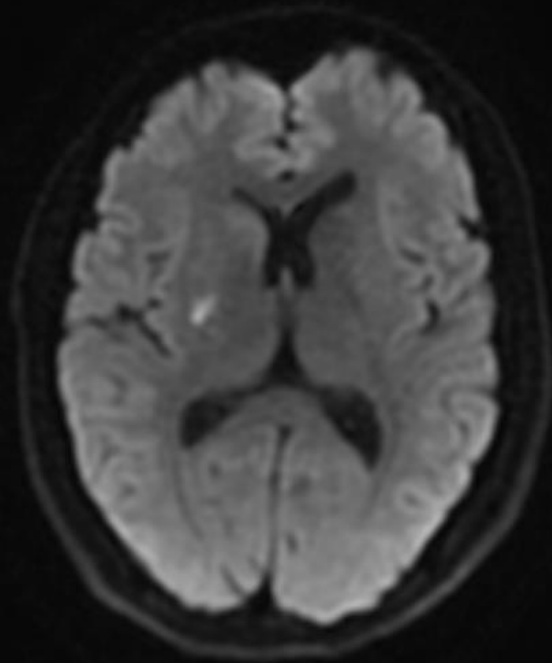


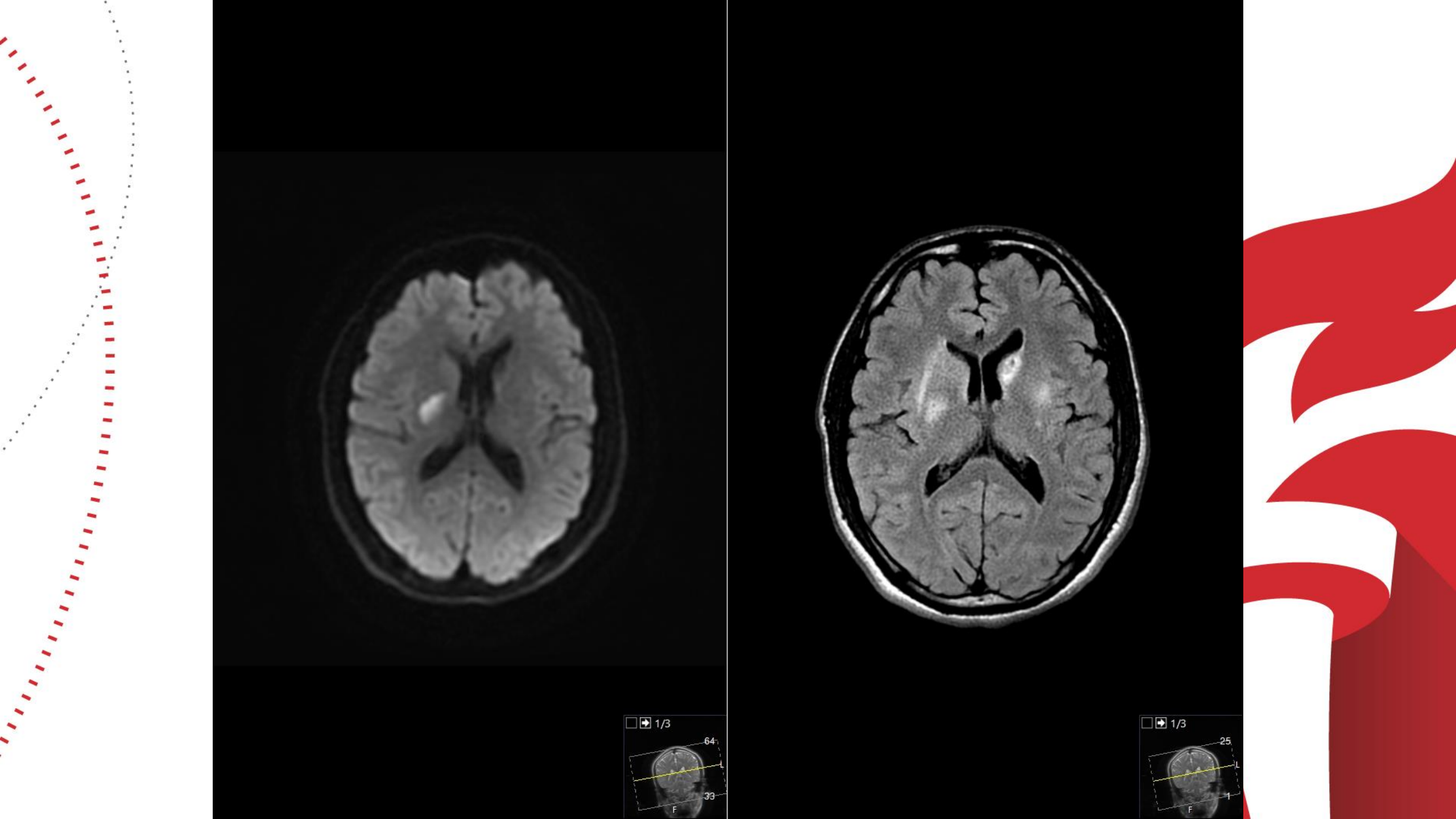
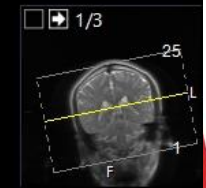
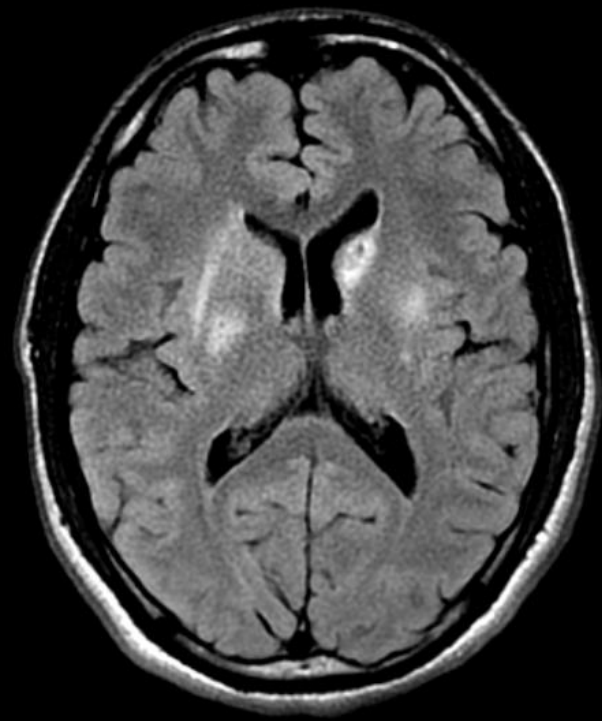
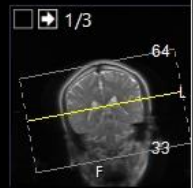
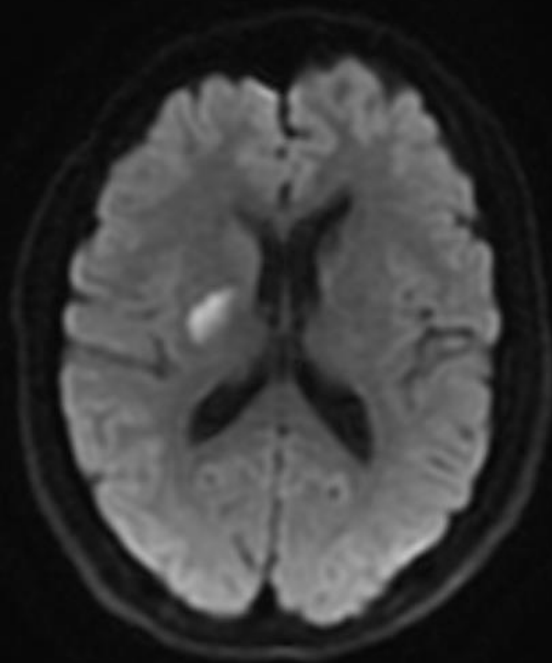


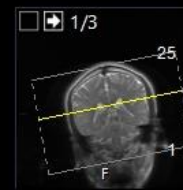
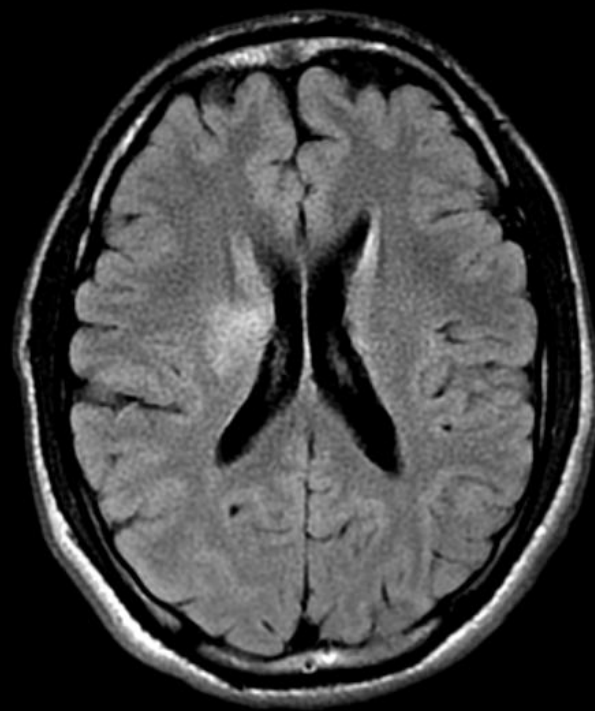
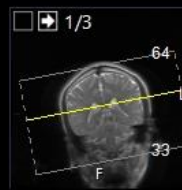
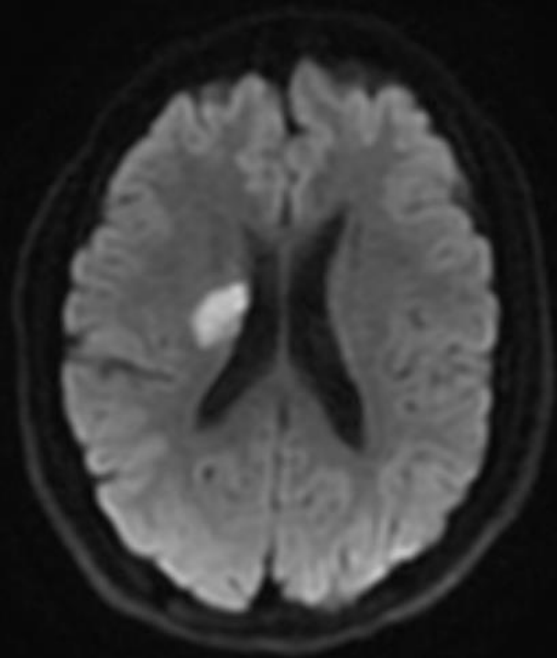


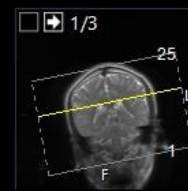
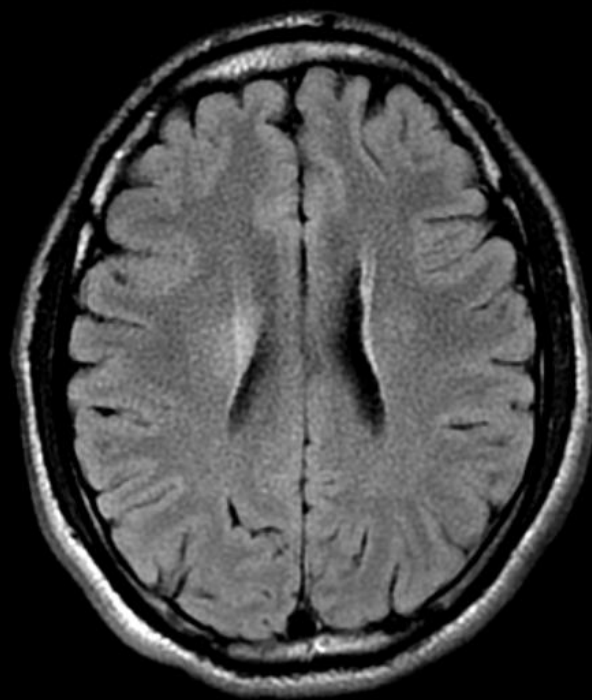
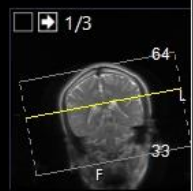
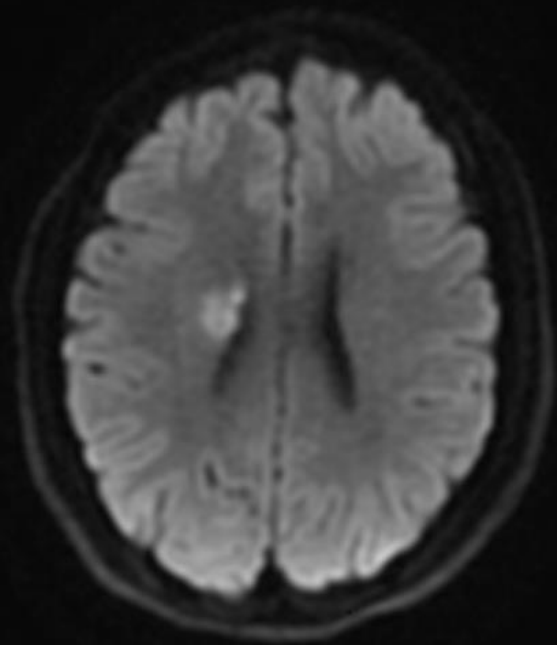


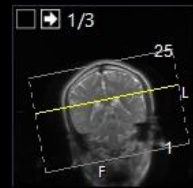
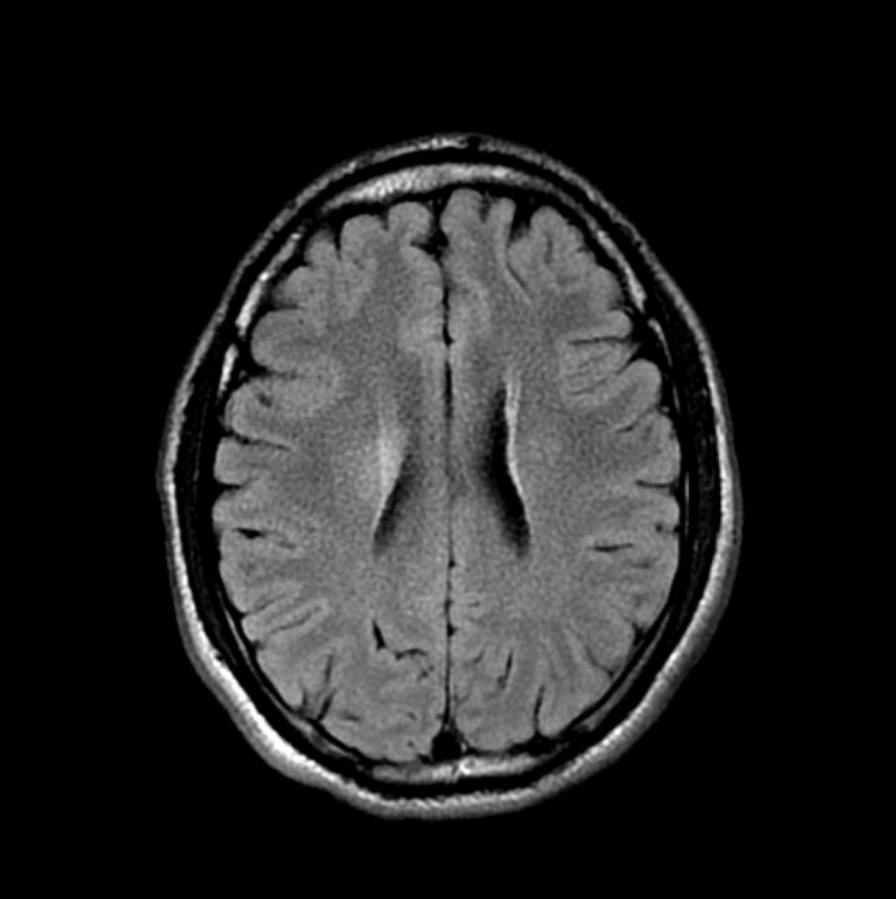
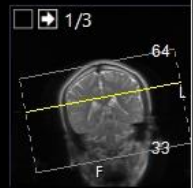
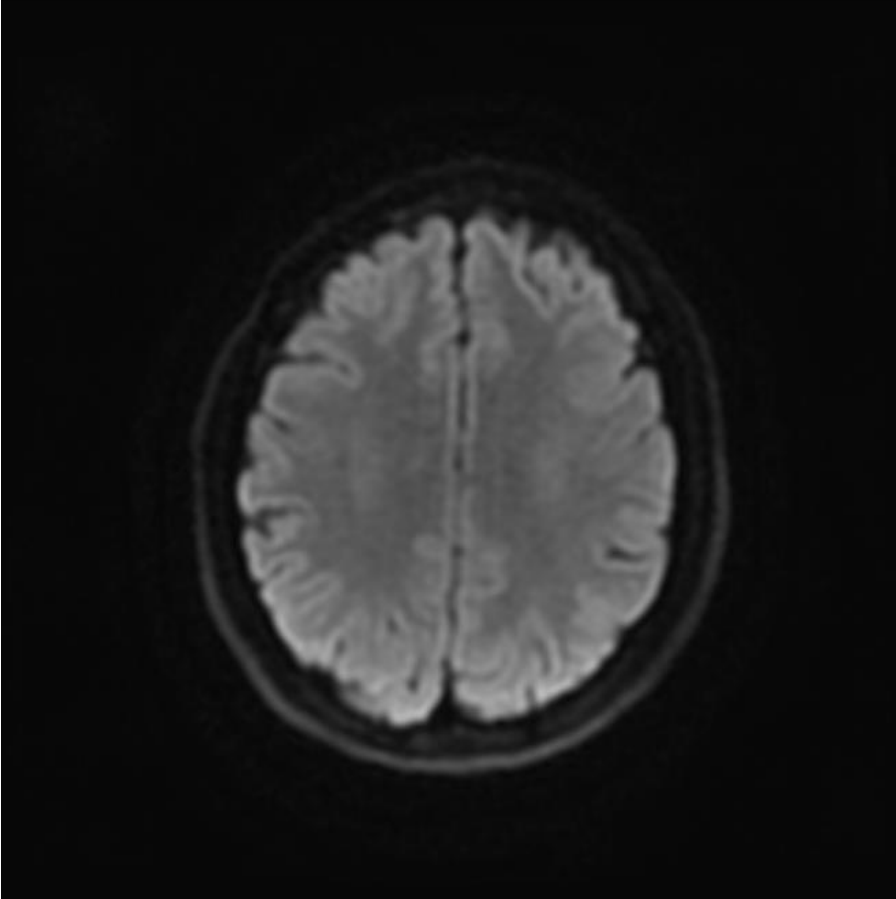
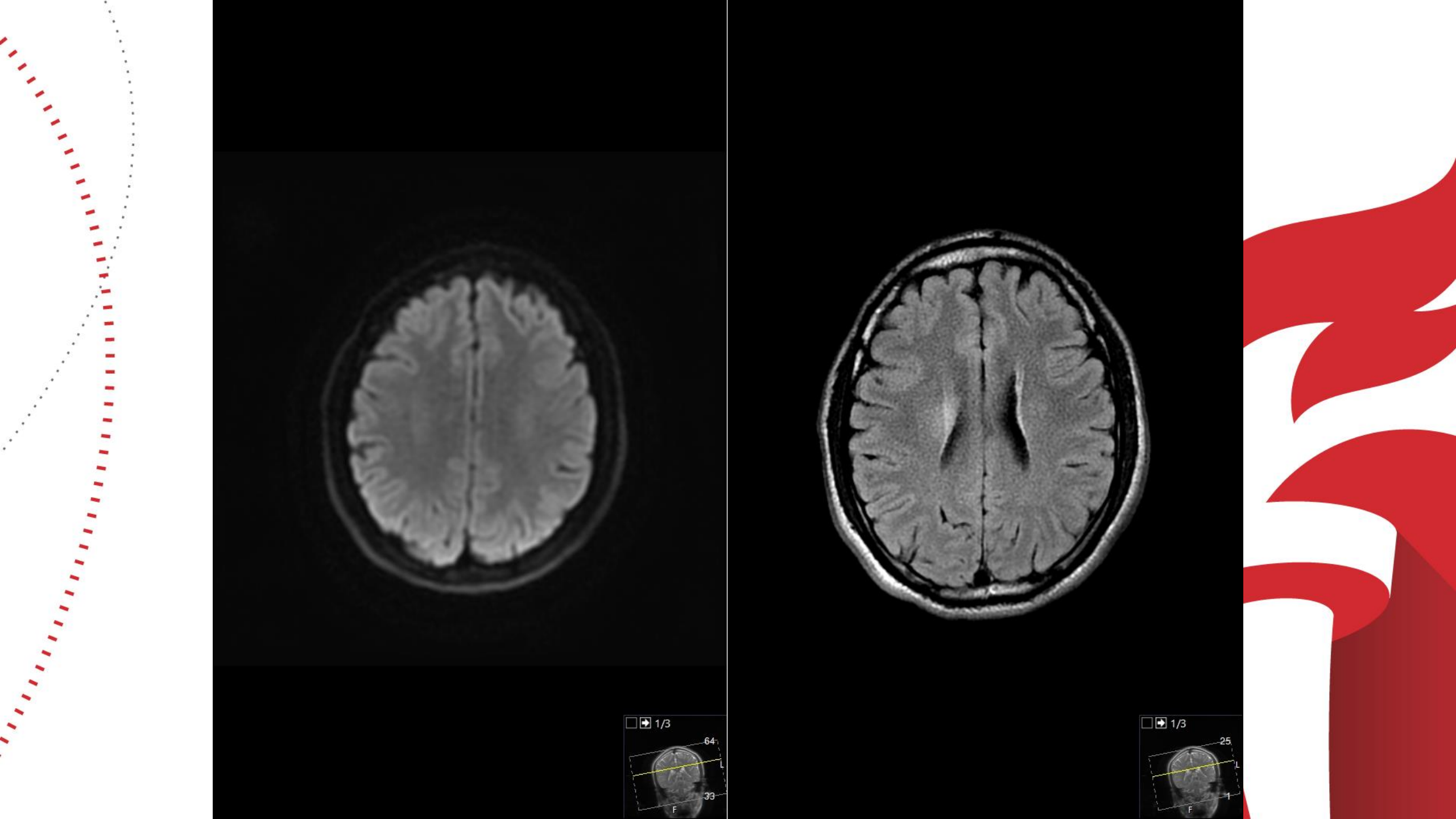


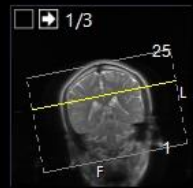
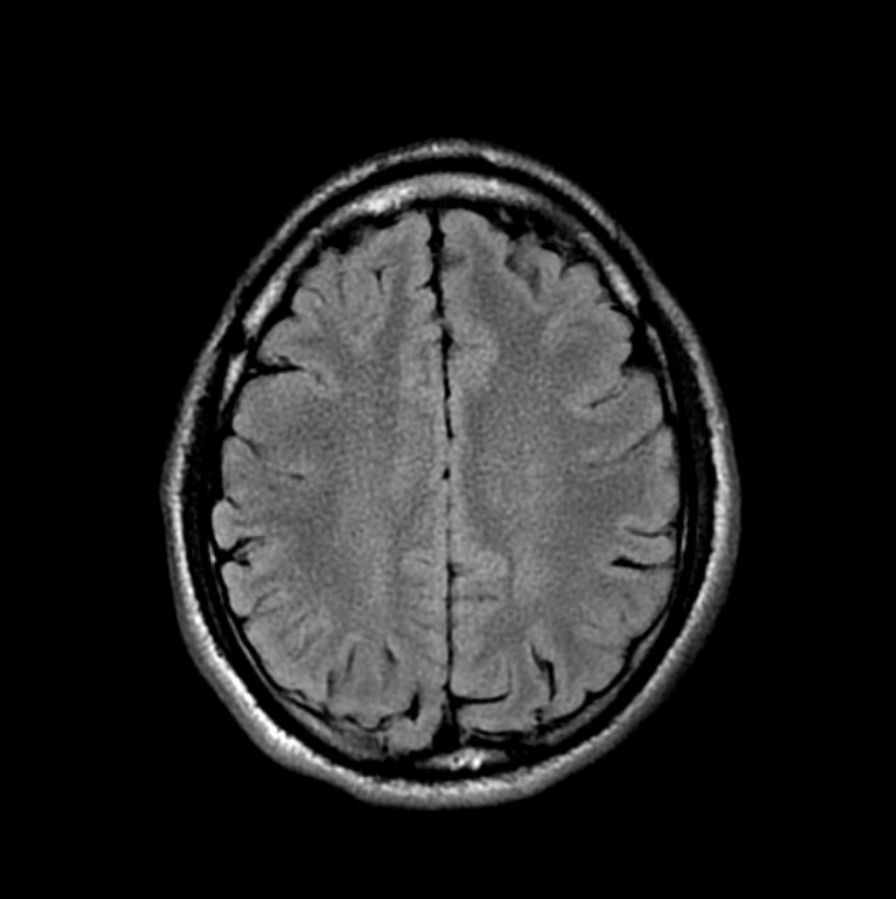
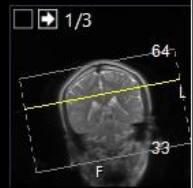
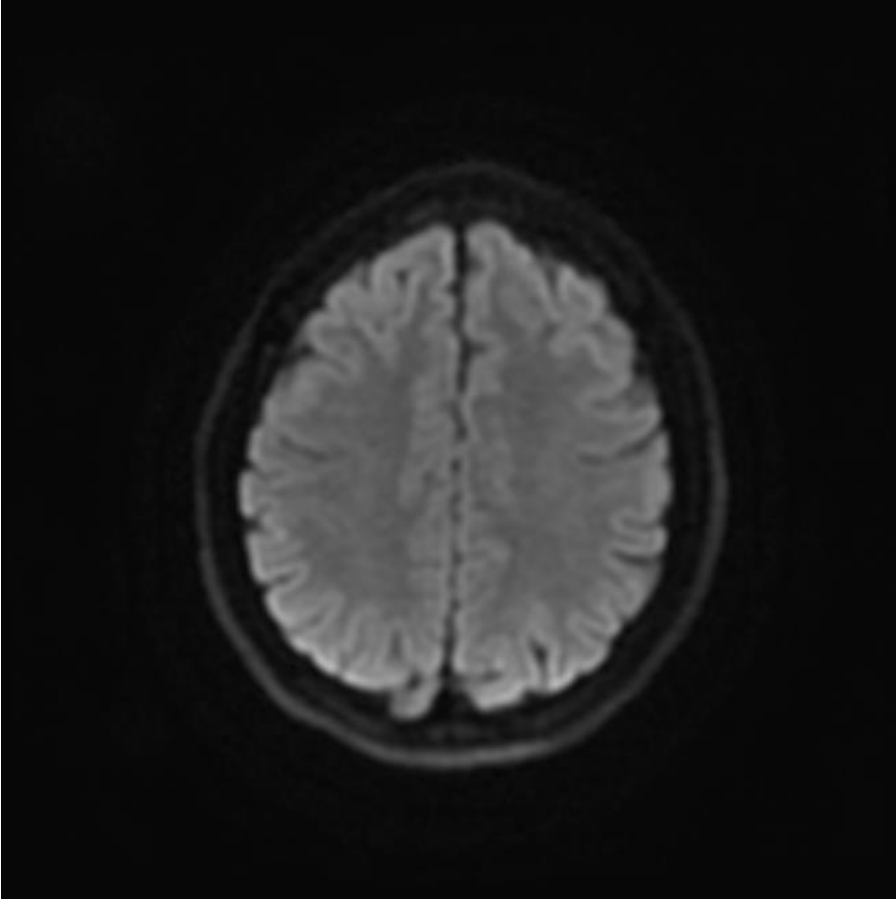
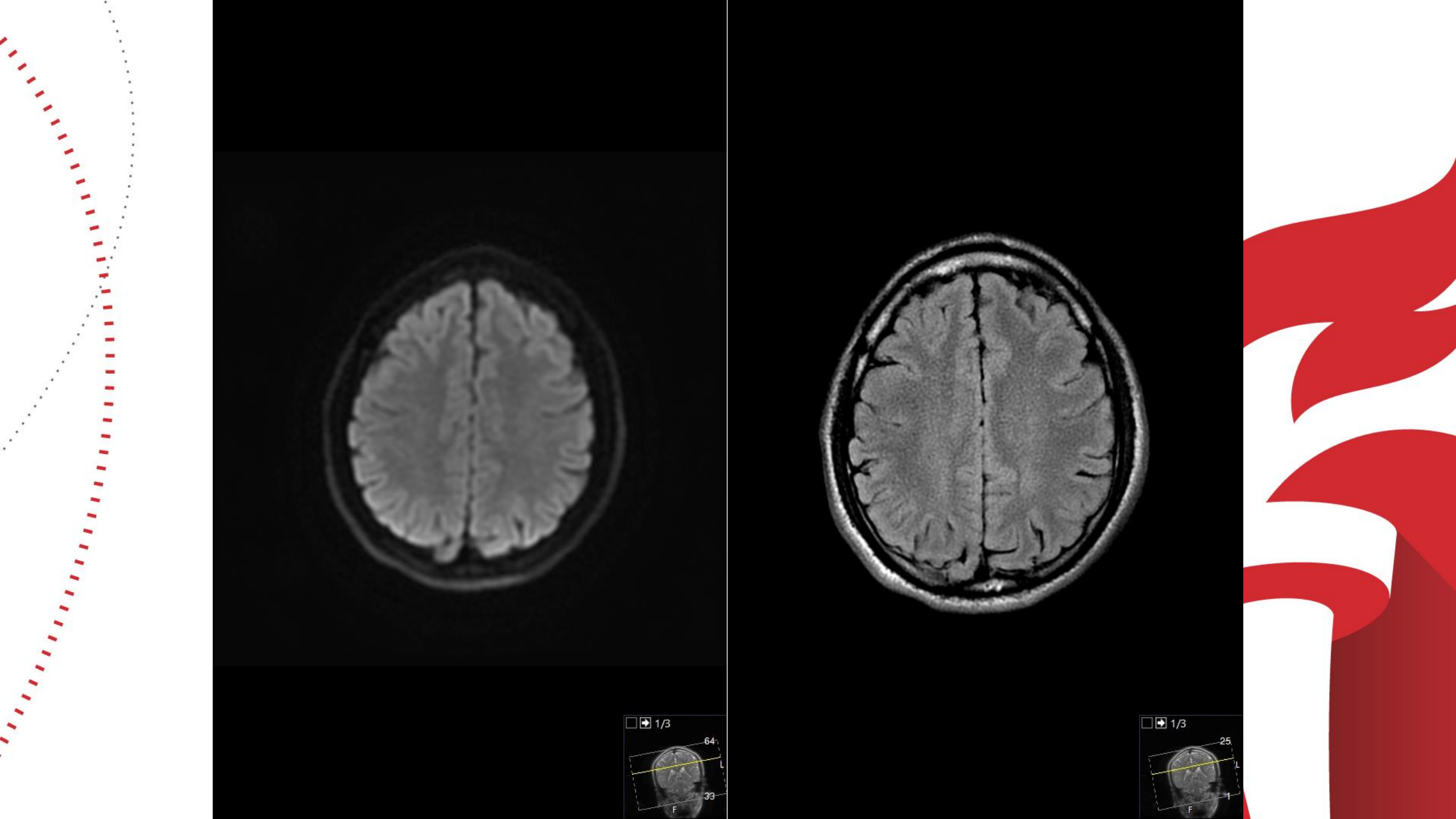


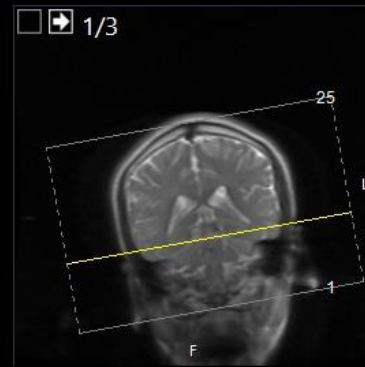
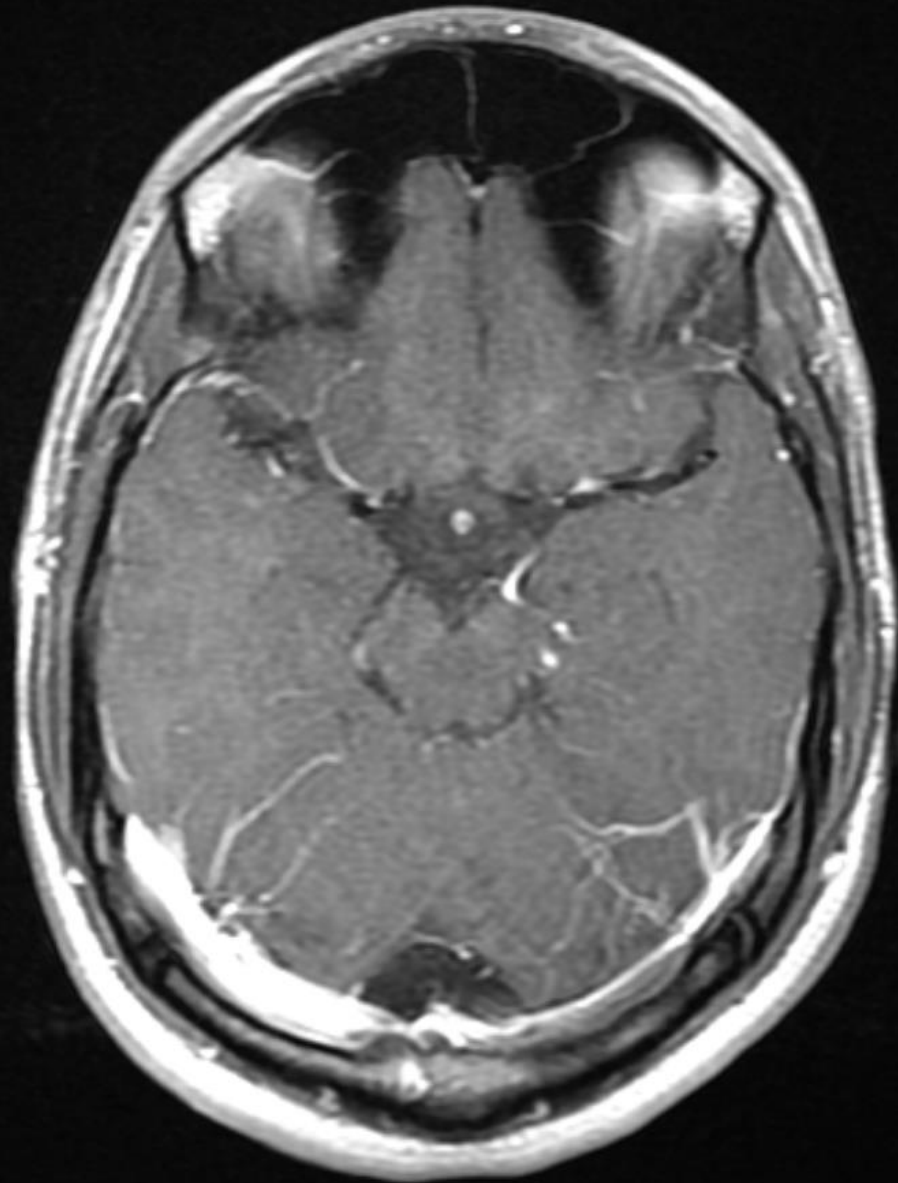


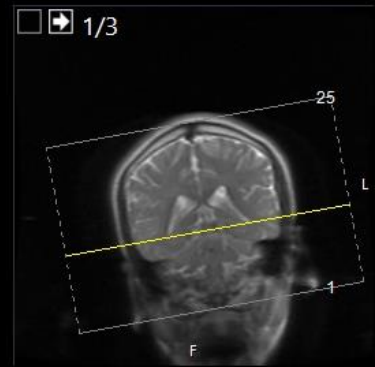
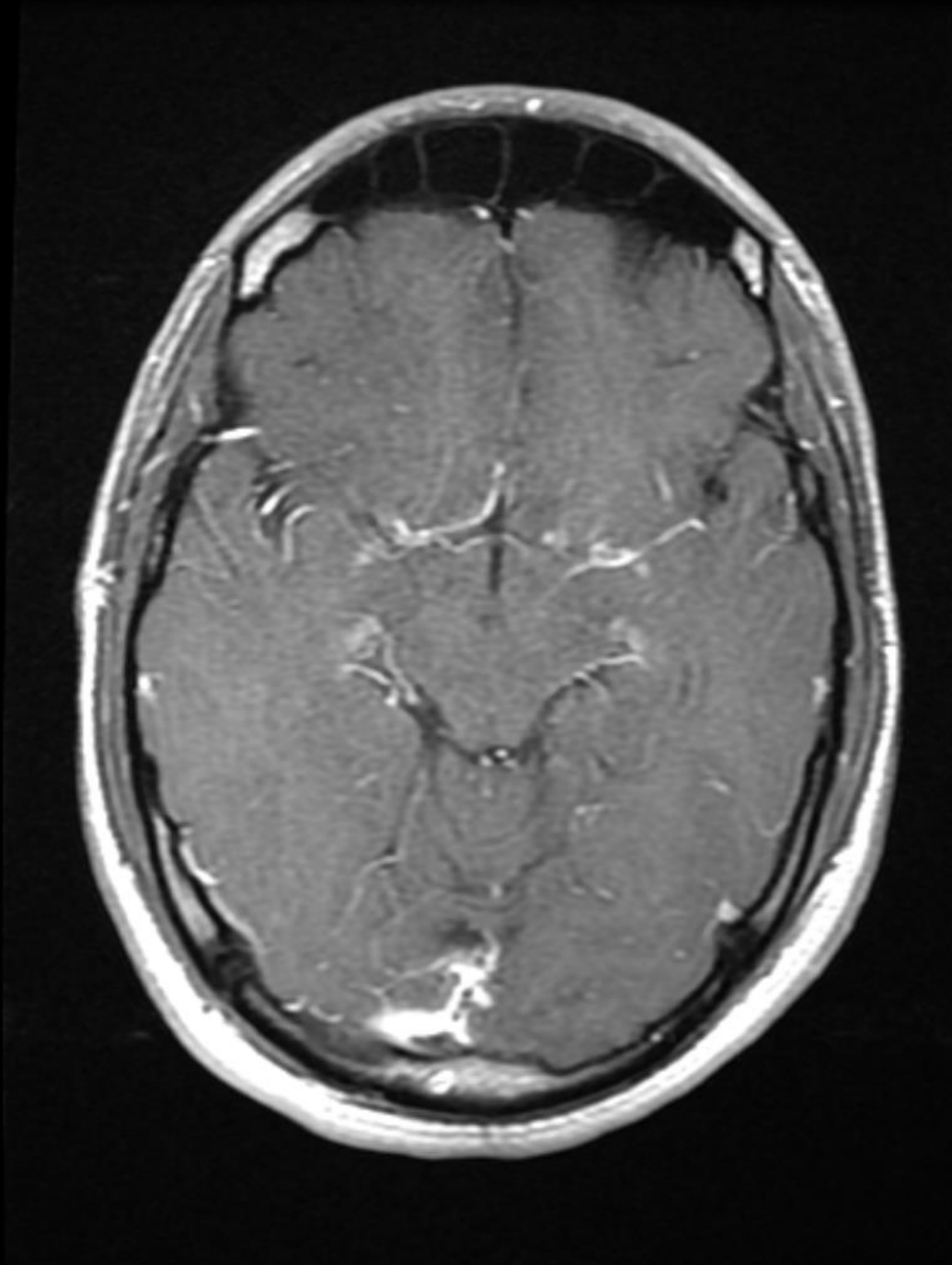
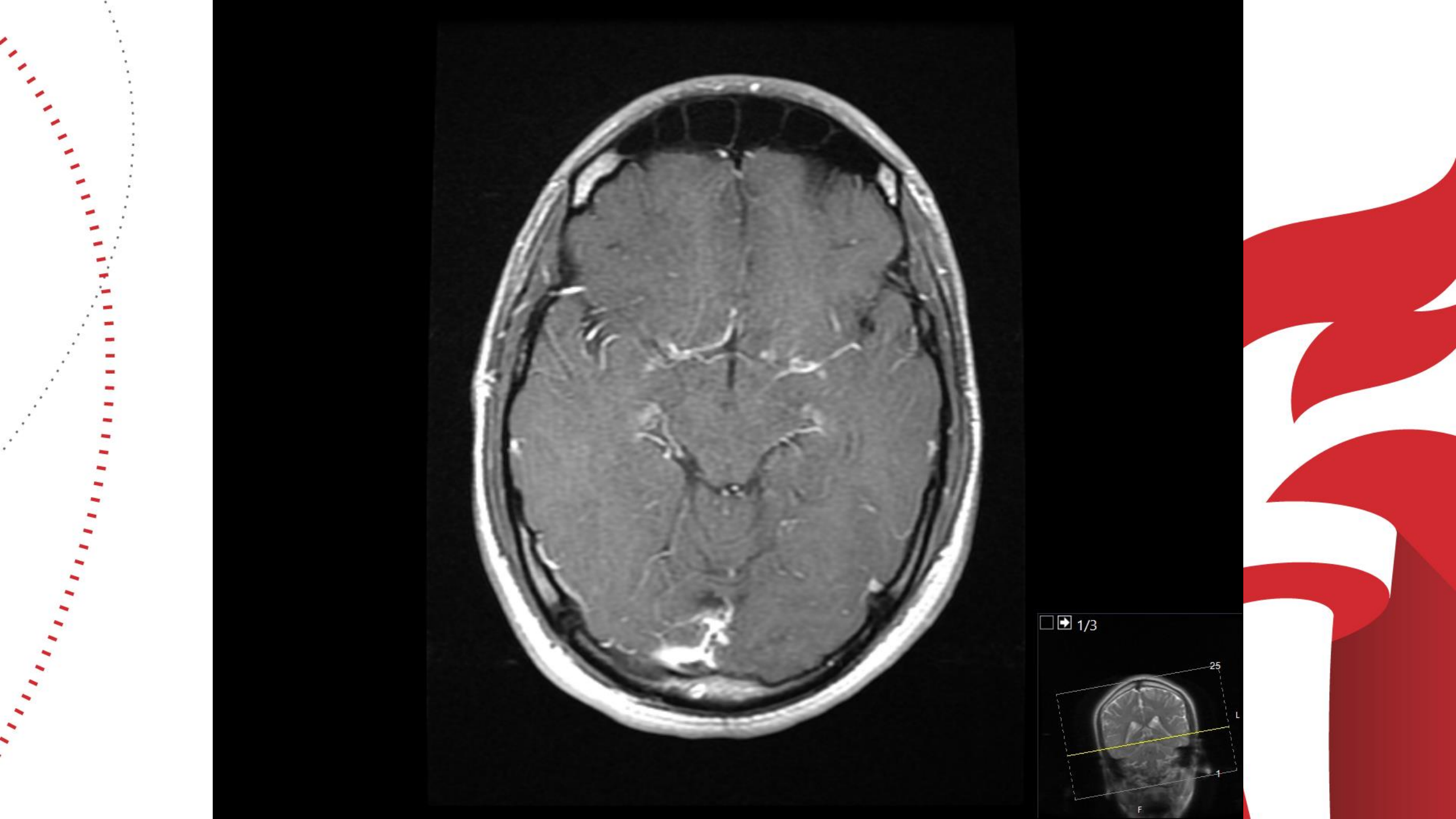


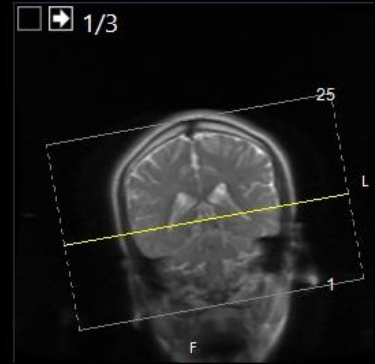
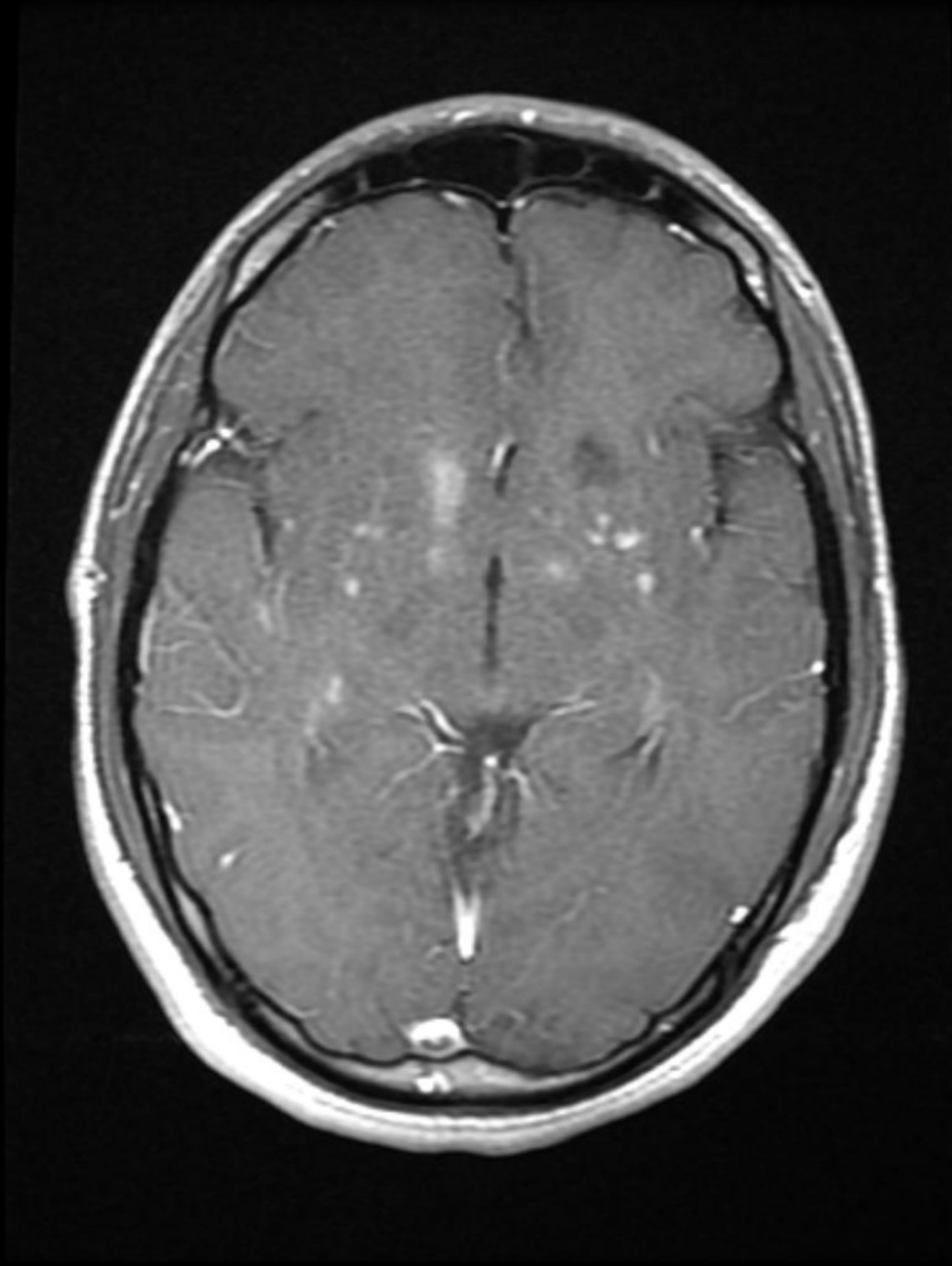
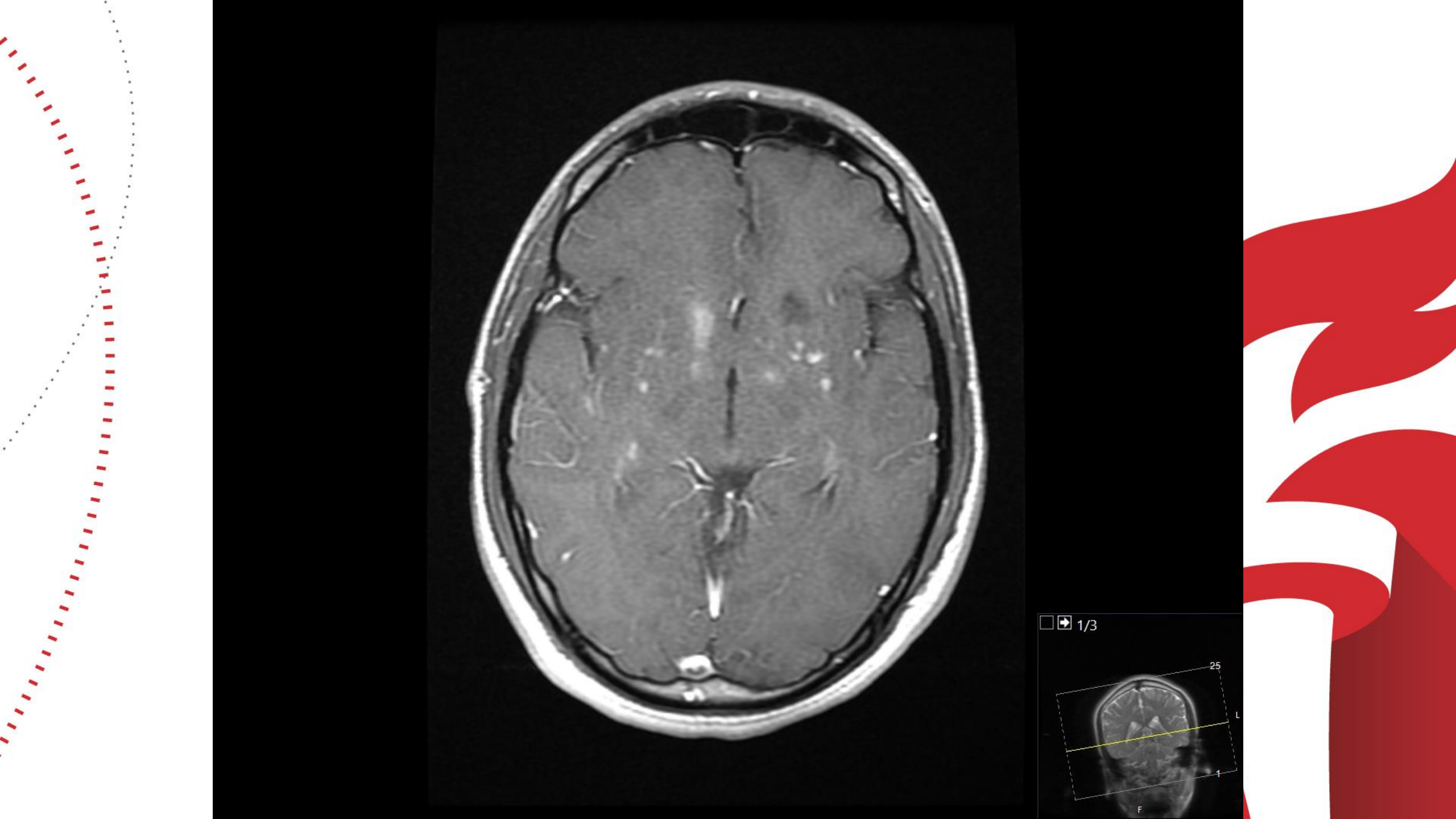


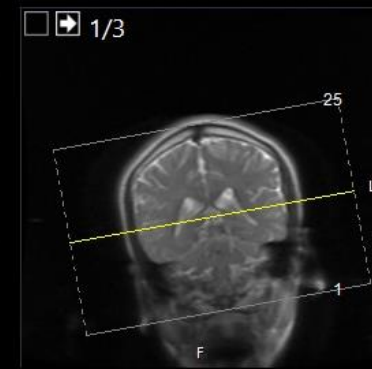
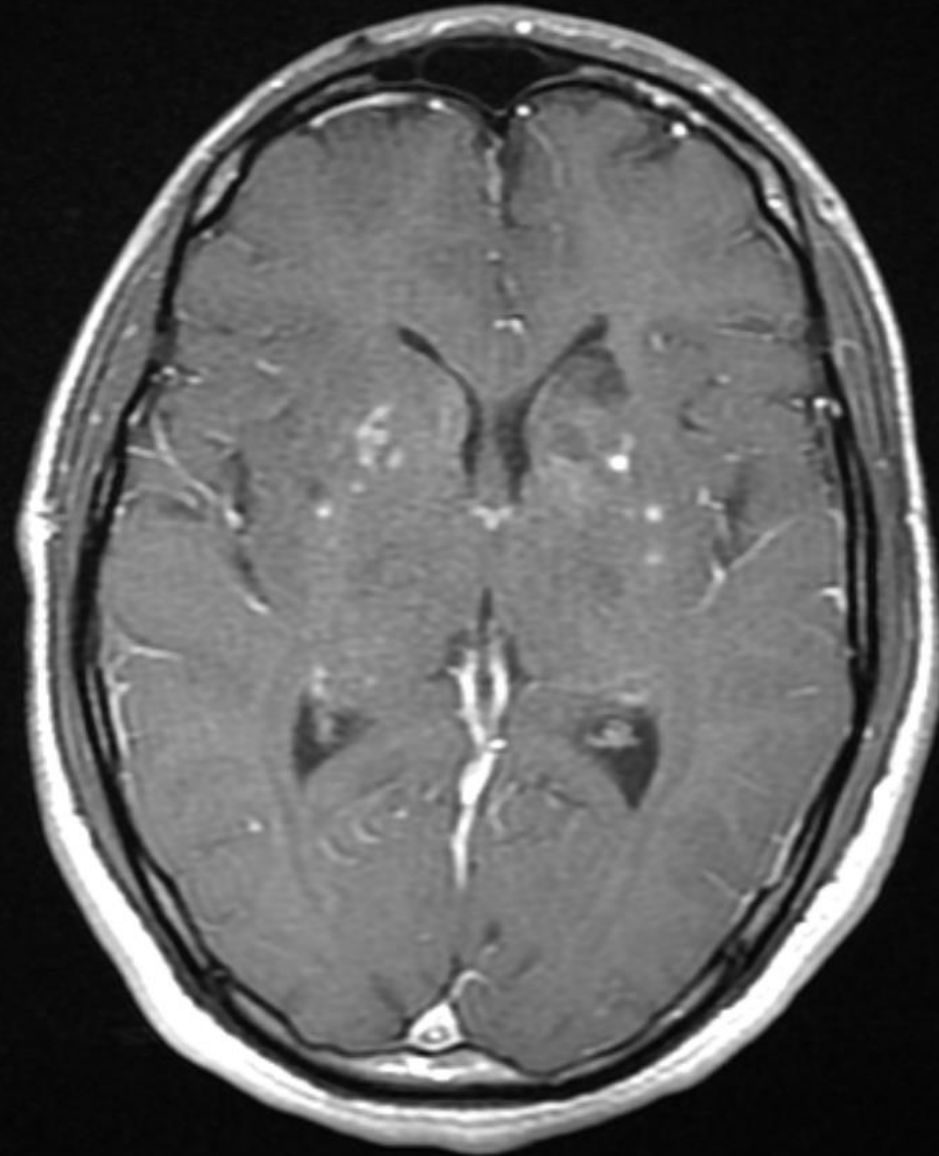


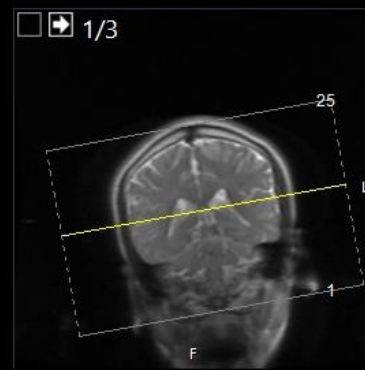
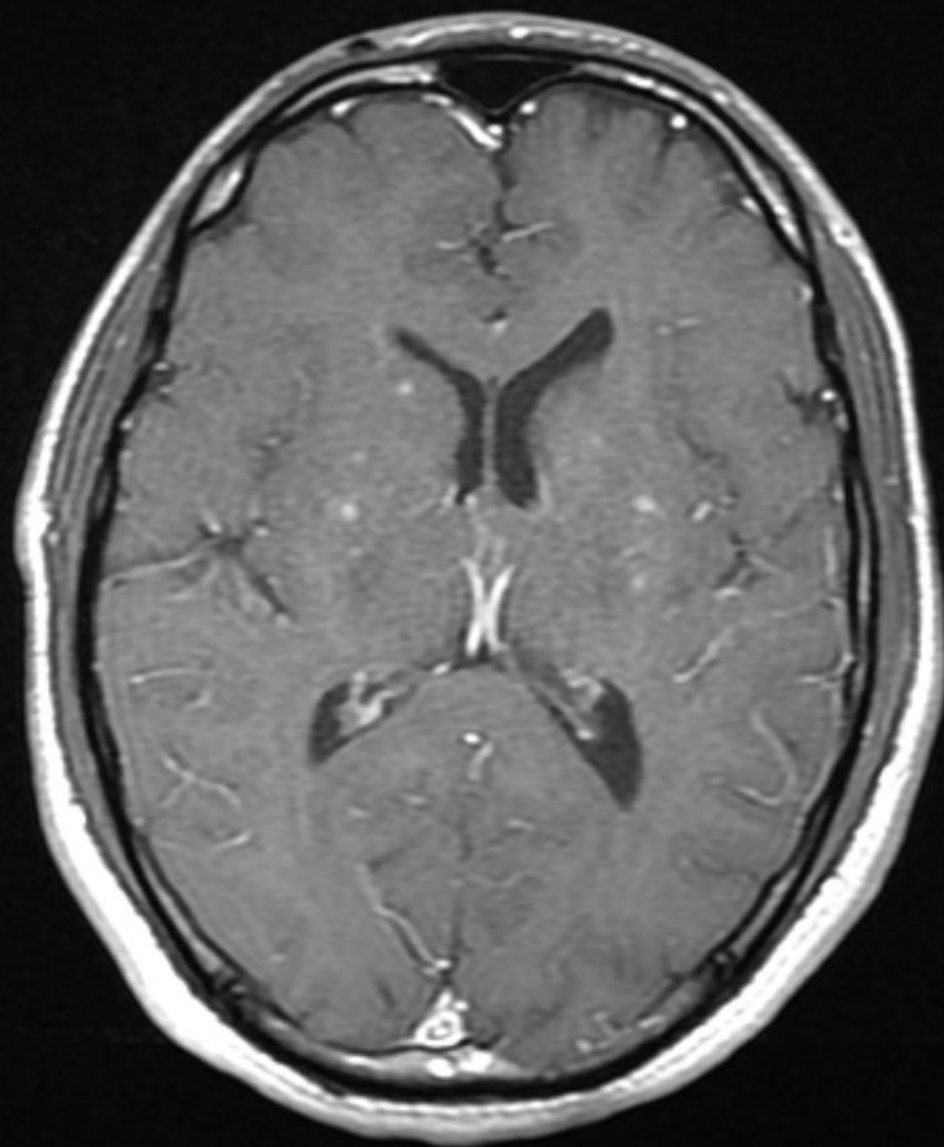


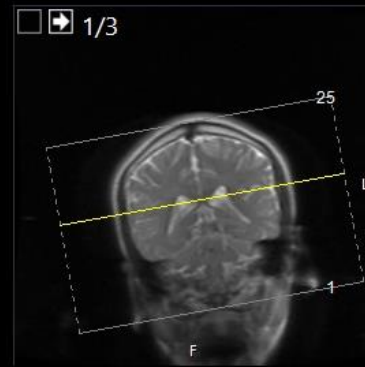
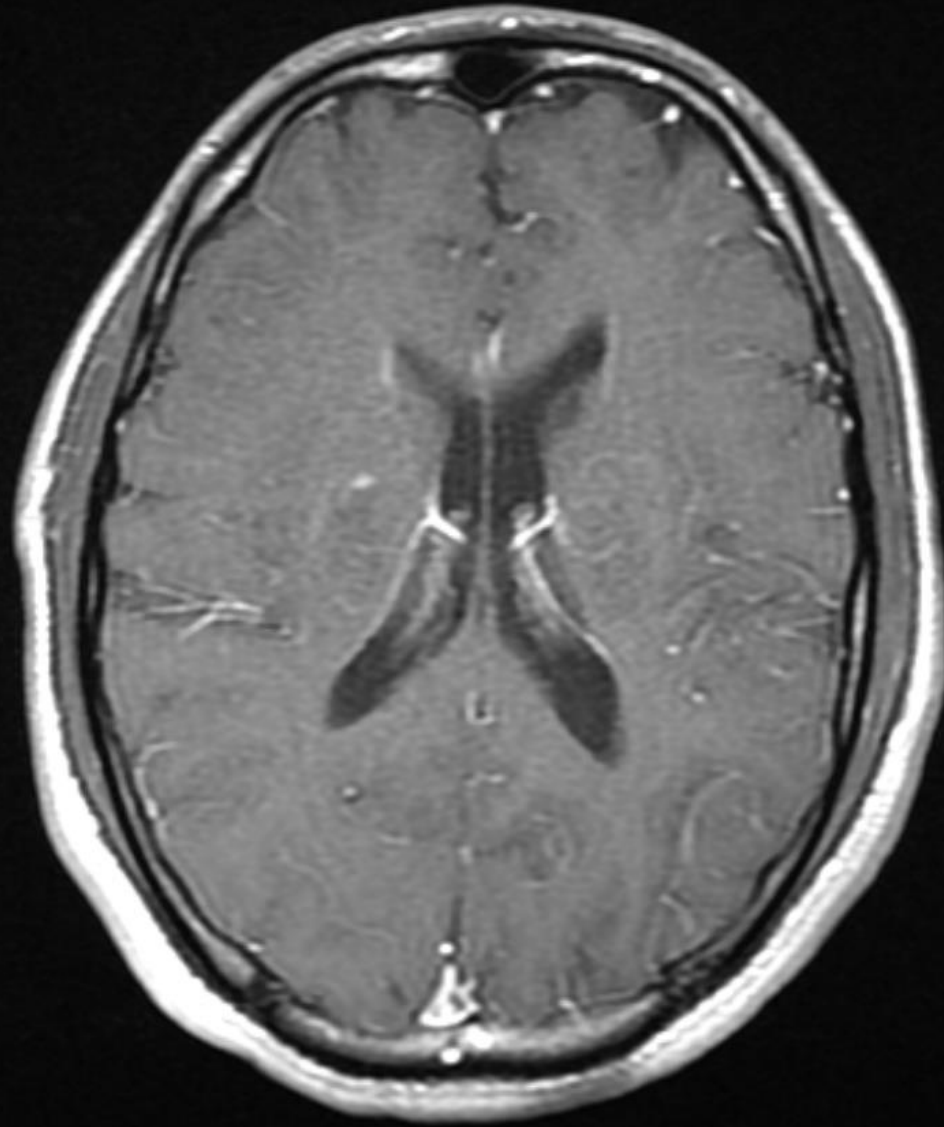


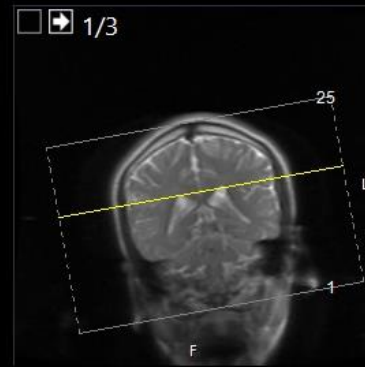
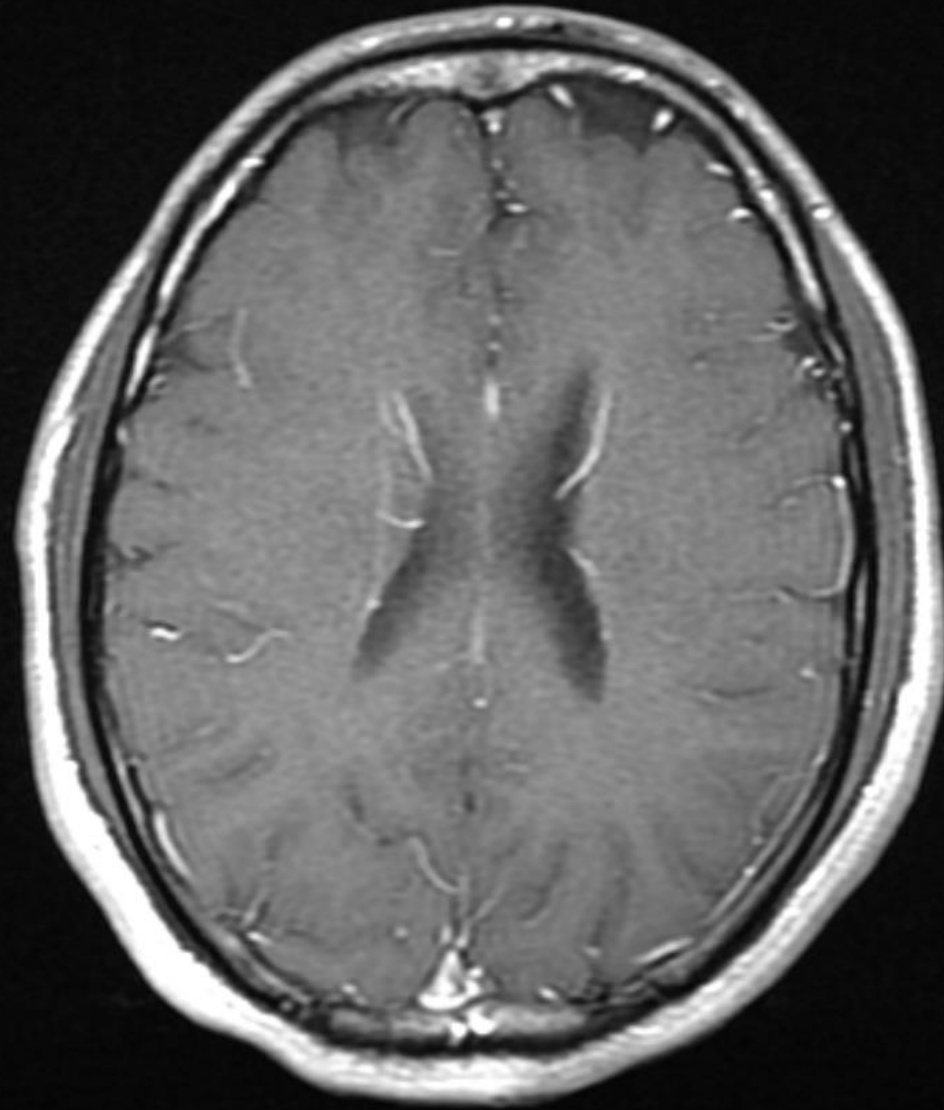
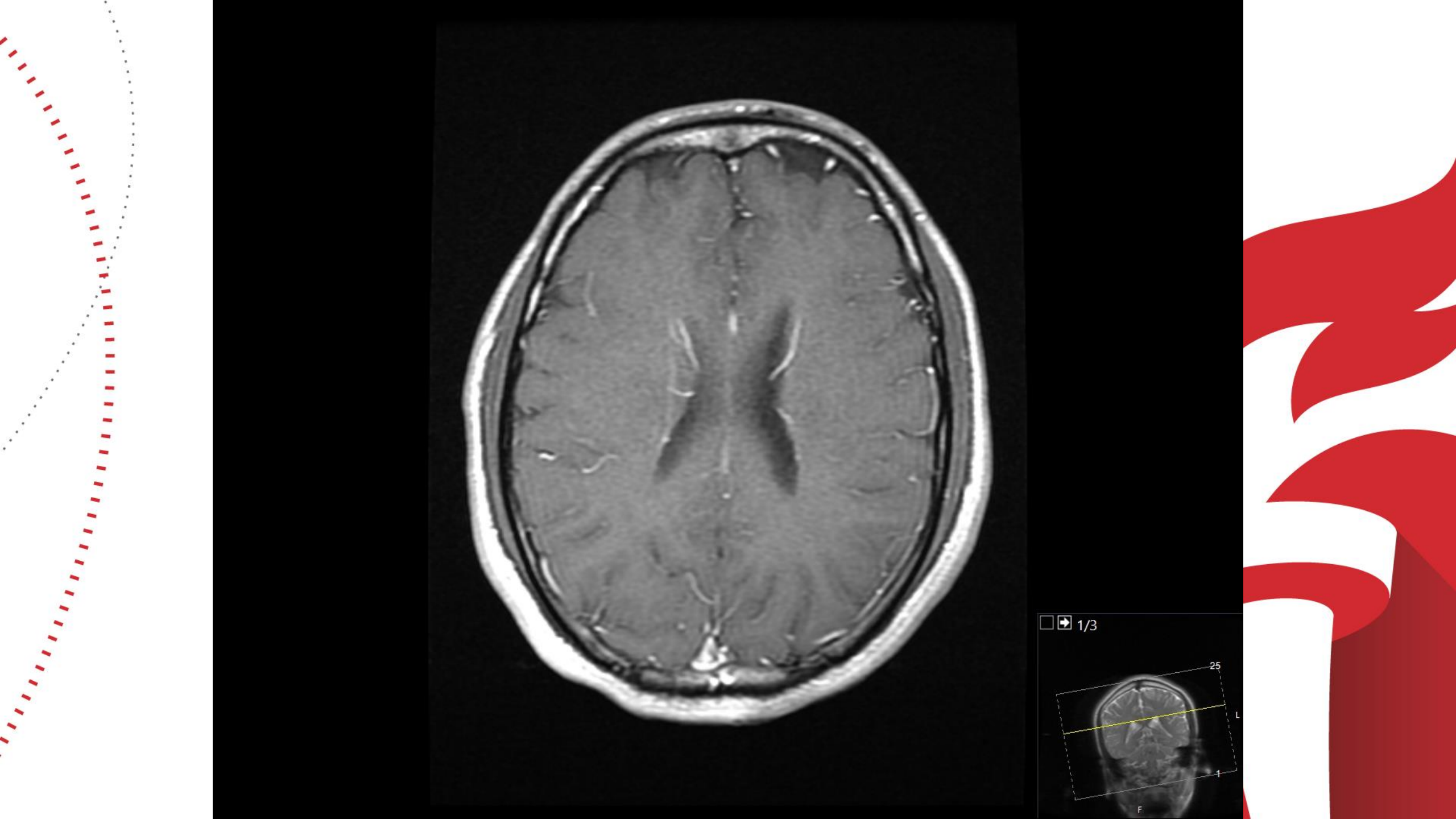












CASE 1

GIVEN SORE THROAT, COVID SWAB DONE AND PCR+
LP DONE AND CSF UNREMARKABLE

BROAD SEROLOGIC TESTING FOR OTHER
INFECTIOUS/INFLAMMATORY DISEASE NEGATIVE

EMPIRICALLY TREATED WITH PREDNISON 60 MG DAILY

AT FOLLOW-UP 2 WEEKS POST DISCHARGE, MINIMAL
RESIDUAL L LEG WEAKNESS BUT OTHERWISE
ASYMPTOMATIC

CASE 1

WHAT IS THIS????

PERIVASCULAR ENHANCEMENT ON MRI AND SYMMETRIC BASAL GANGLIA SIGNAL ABNORMALITY SUGGEST VASCULAR INFECTIOUS/INFLAMMATORY PROCESS, ? COVID ENDOTHELIAL-ITIS?

ACUTE INFARCTIONS LIKELY RELATED TO THIS

F/U IMAGING PENDING

Endothelial invasion with COVID

(Varga Z, Lancet 2020)

Endothelial cell infection and endotheliitis in COVID-19

Cardiovascular complications are rapidly emerging as a key threat in coronavirus disease 2019 (COVID-19) in addition to respiratory disease. The mechanisms underlying the disproportionate effect of severe acute respiratory syndrome coronavirus 2 (SARS-CoV-2) infection on patients with cardiovascular comorbidities, however, remain incompletely understood.^{1,2}

SARS-CoV-2 infects the host using the angiotensin converting enzyme 2 (ACE2) receptor, which is expressed in several organs, including the lung, heart, kidney, and intestine. ACE2 receptors are also expressed by endothelial cells.³ Whether vascular derangements in COVID-19 are due to endothelial cell involvement by the virus is currently unknown. Intriguingly, SARS-CoV-2

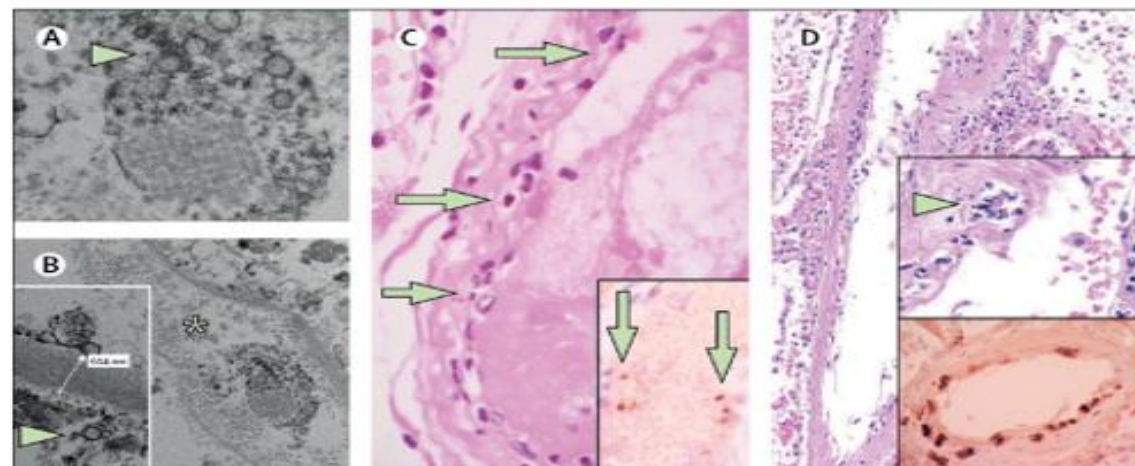


Figure: Pathology of endothelial cell dysfunction in COVID-19

(A, B) Electron microscopy of kidney tissue shows viral inclusion bodies in a peritubular space and viral particles in endothelial cells of the glomerular capillary loops. Aggregates of viral particles (arrow) appear with dense circular surface and lucid centre. The asterisk in panel B marks peritubular space consistent with capillary containing viral particles. The inset in panel B shows the glomerular basement membrane with endothelial cell and a viral particle (arrow; about 150 nm in diameter). (C) Small bowel resection specimen of patient 3, stained with haematoxylin and eosin. Arrows point to dominant mononuclear cell infiltrates within the intima along the lumen of many vessels. The inset of panel C shows an immunohistochemical staining of caspase 3 in small bowel specimens from serial section of tissue described in panel D. Staining patterns were consistent with apoptosis of endothelial cells and mononuclear cells observed in the haematoxylin-eosin-stained sections, indicating that apoptosis is induced in a substantial proportion of these cells. (D) Post-mortem lung specimen stained with haematoxylin and eosin showed thickened lung septa, including a large arterial vessel with mononuclear and neutrophilic infiltration (arrow in upper inset). The lower inset shows an immunohistochemical staining of caspase 3 on the same lung specimen; these staining patterns were consistent with apoptosis of endothelial cells and mononuclear cells observed in the haematoxylin-eosin-stained sections. COVID-19=coronavirus disease 2019.



Published Online
April 17, 2020
[https://doi.org/10.1016/S0140-6736\(20\)30937-5](https://doi.org/10.1016/S0140-6736(20)30937-5)



A Teaching Affiliate
of Harvard Medical School

COVID-19 and Stroke

Cases and Discussion

AHA Webinar, 2020

T.M. (Bay) Leslie-Mazwi, M.D.
Director of Endovascular Stroke Services
Neuroendovascular | Neurologic Critical Care
Massachusetts General Hospital
Harvard Medical School
Boston, MA



MASSACHUSETTS
GENERAL HOSPITAL

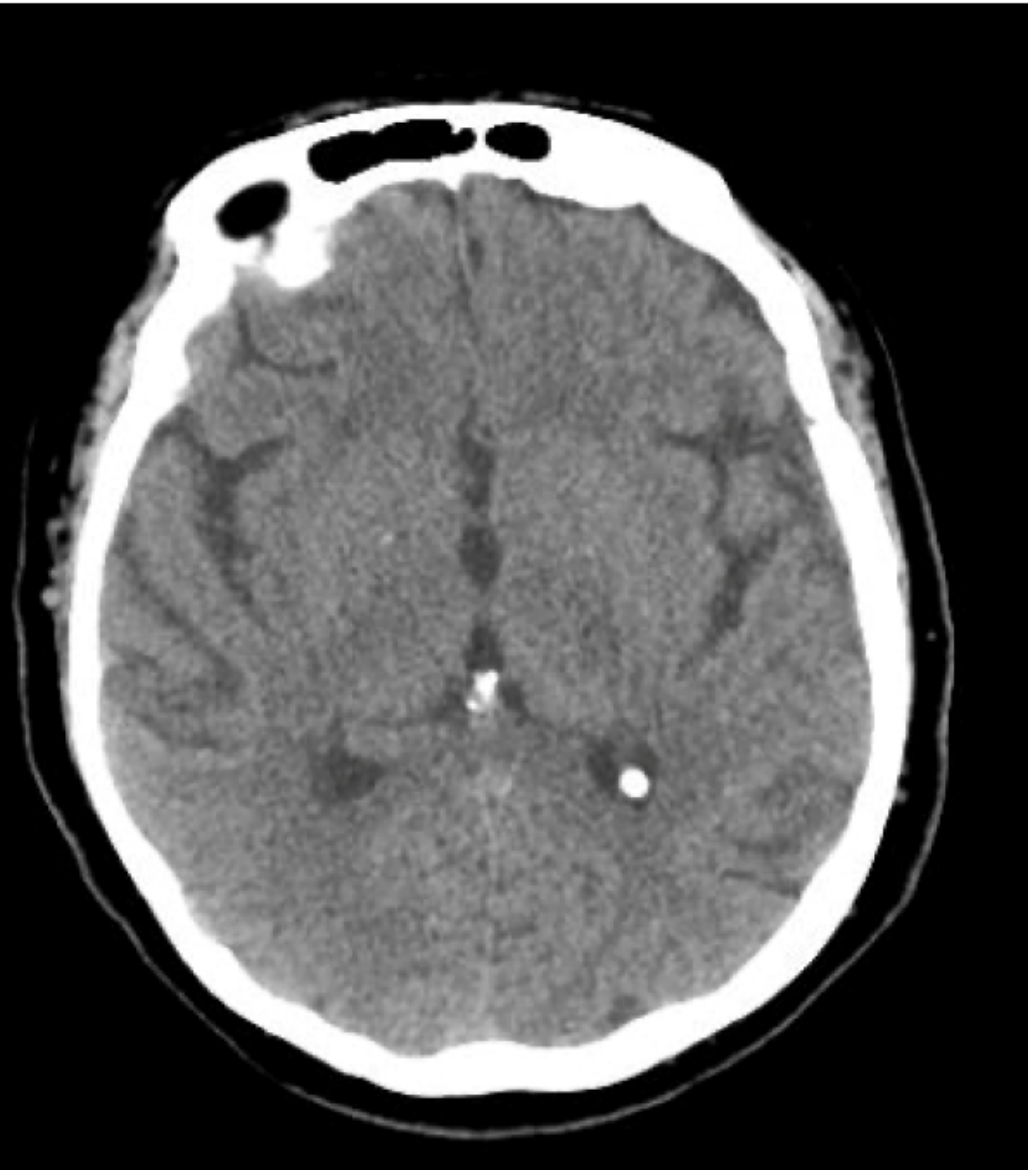
FIREMAN VASCULAR CENTER

Case Presentation

- 69 y.o. female with COPD, DM type II
- Presenting to OSH with fever and chills
- No known COVID-19 exposure
- COVID-19 positive (nasal swab x 1)
- Admitted for 10 days of hydroxychloroquine and azithromycin
- Worsened respiratory status led to ICU transfer day 8
- On ICU transfer Head CT for delirium



Brain Imaging for Neurological Complaints



Approximately 6% of COVID-19 positive patients with neurological symptoms will have positive findings on cerebral imaging
Not clear age predilection

Unclear what the denominator is, and therefore what the true incidence is of positive findings

→ **Low threshold for imaging**

Yanan Li MW, et al. Acute cerebrovascular disease following COVID-19: a single center, retrospective, observational study. *Lancet* 2020



MASSACHUSETTS
GENERAL HOSPITAL

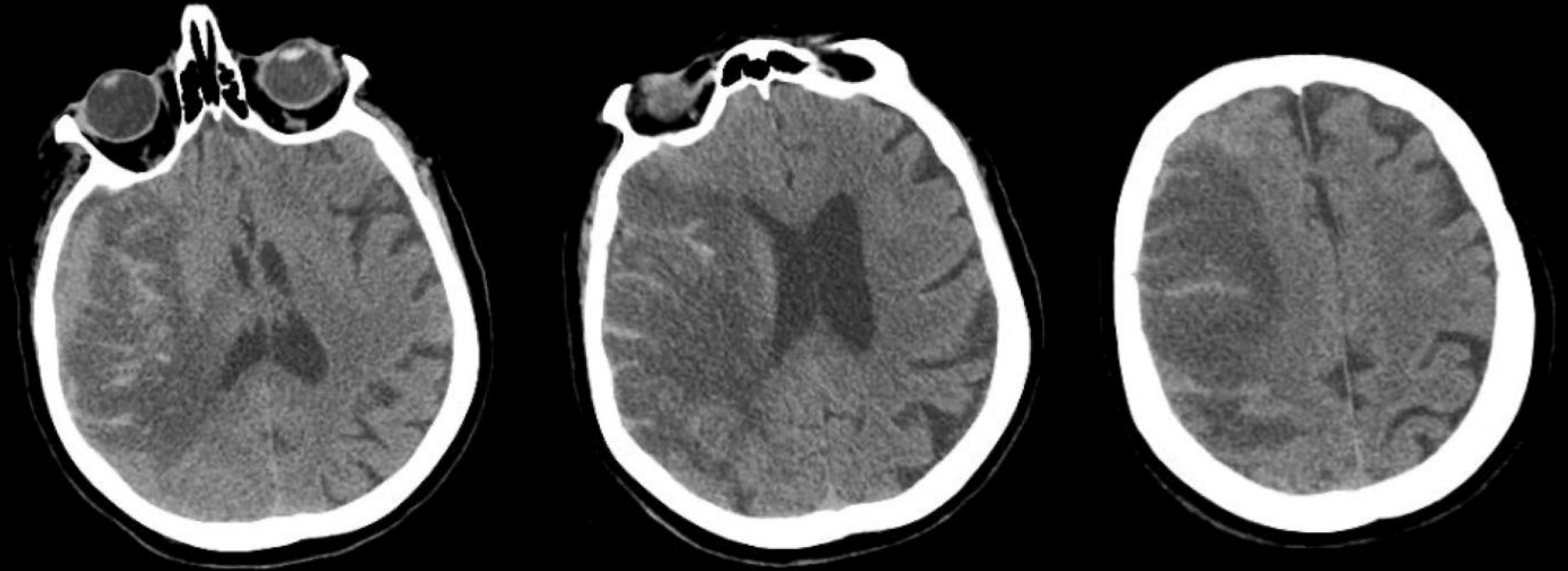
FIREMAN VASCULAR CENTER

ICU Course

- Intubation day 9. Severe hypoxia, prone on day 11, with repeated cycles of paralytic and proning
- Renal function worsened day 11, eventually **required dialysis** day 15
- Persistent fever, repeat COVID-19 nasal swab negative, diagnosed with **Rt femoral DVT** day 20
 - What are rates of DVT/PE in COVID-19 patients?
- Escalated heparin prophylaxis to **therapeutic AC**
- Day 26, sedation weaned, **left sided weakness**



Head CT



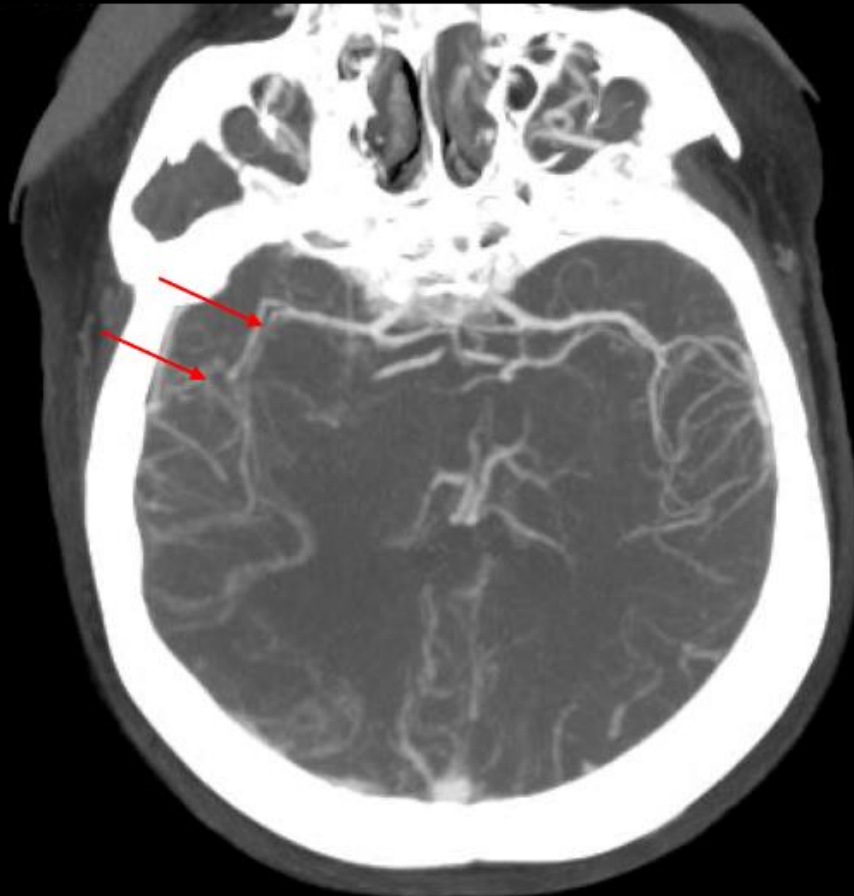Large Rt MCA stroke with hemorrhagic conversion



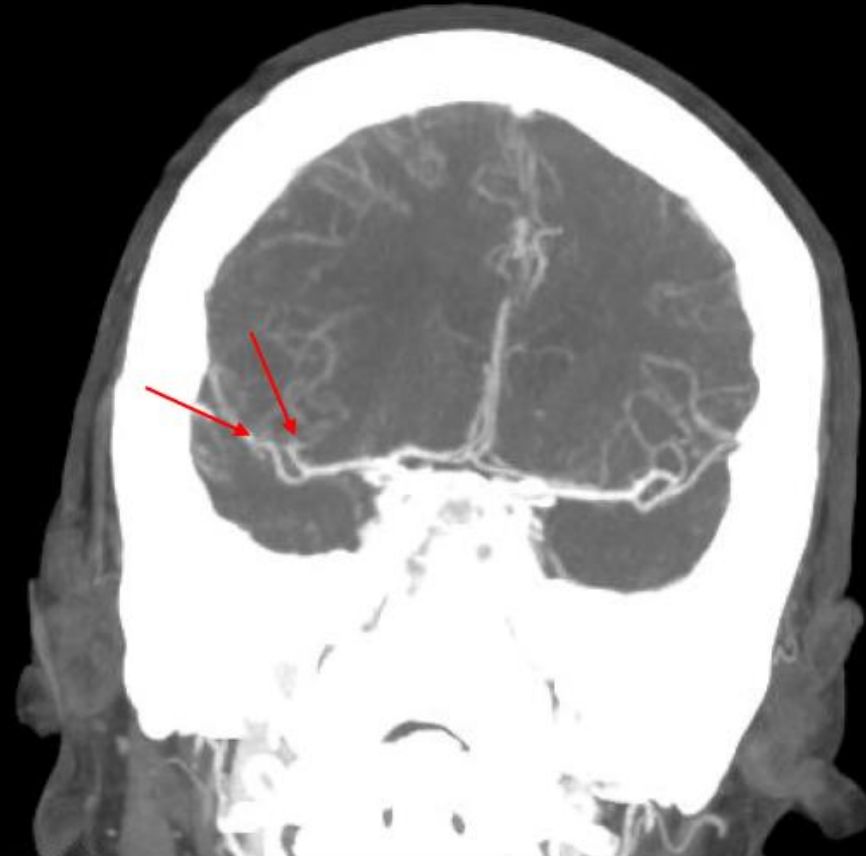MASSACHUSETTS
GENERAL HOSPITAL

FIREMAN VASCULAR CENTER

Head CTA



Axial MIPs



Coronal MIPs

Mid-distal Rt M2 occlusions



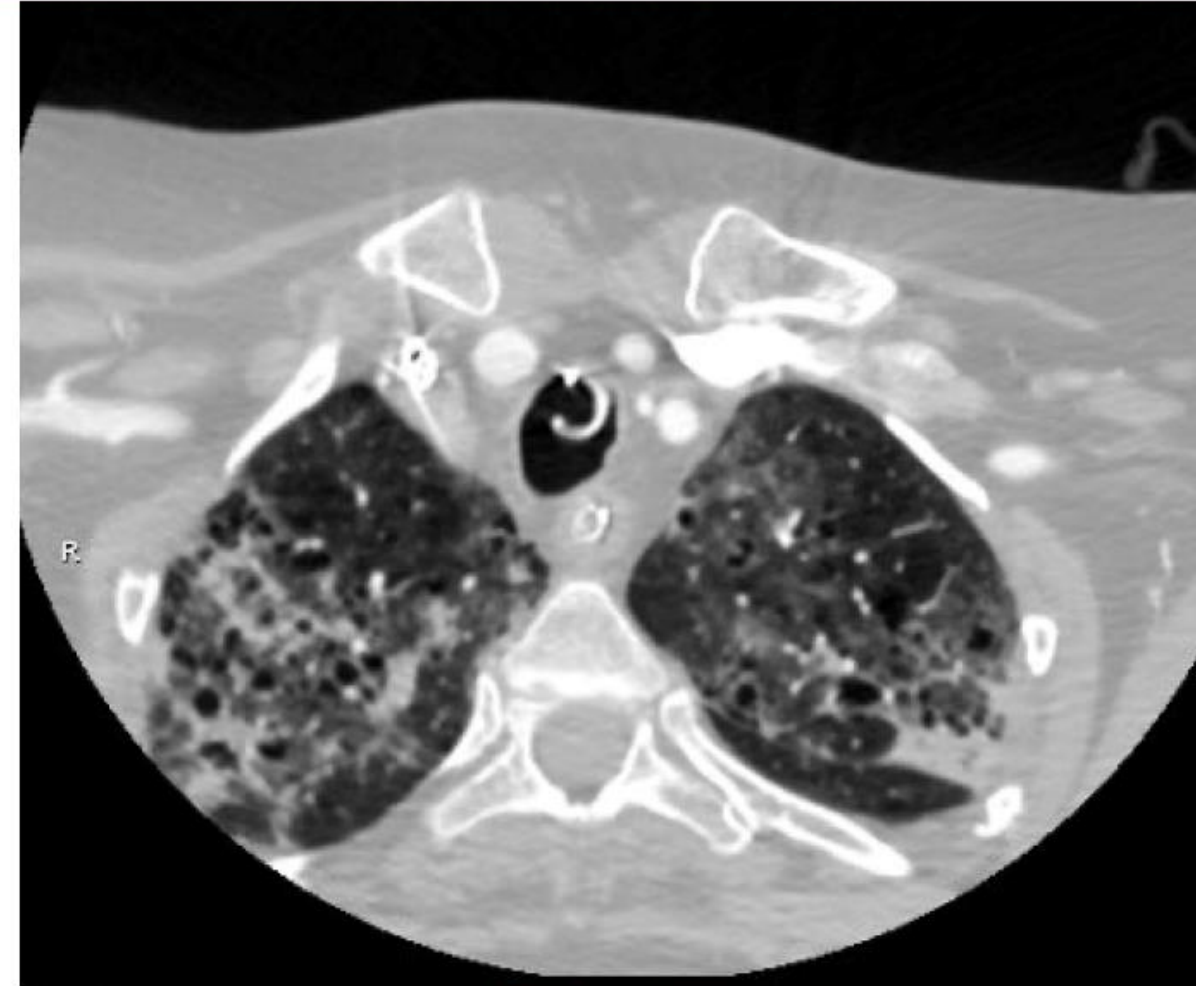MASSACHUSETTS
GENERAL HOSPITAL

FIREMAN VASCULAR CENTER

Lung Apices on CTA

CT chest abnormalities demonstrate high sensitivity in COVID-19 (97%)

The role of adding CT Chest to CT brain imaging for acute stroke eval remains to be clarified



Fang, Y., et al. Sensitivity of chest CT for COVID-19: comparison to RT-PCR. *Radiology* 2020

Ai, T., et al. Correlation of chest CT and RT-PCR testing in coronavirus disease 2019 (COVID-19) in China: a report of 1014 cases. *Radiology* 2020



MASSACHUSETTS
GENERAL HOSPITAL

FIREMAN VASCULAR CENTER

ICU Course

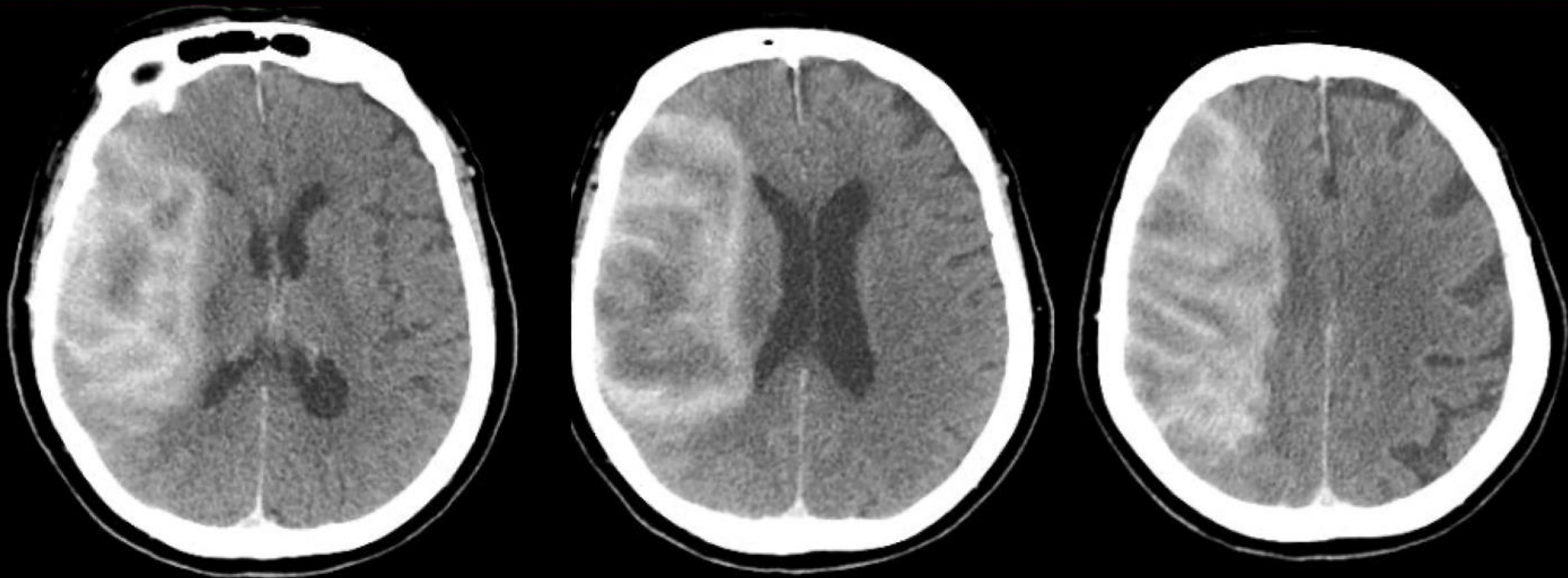
- Not a candidate for acute intervention (thrombolysis or thrombectomy)
- Mannitol boluses initiated (5mm midline shift)
- Heparin stopped, IVC filter placed
- Transfer to CSC initiated
- Head CT repeated at 4 hours given hemorrhagic transformation



MASSACHUSETTS
GENERAL HOSPITAL

FIREMAN VASCULAR CENTER

Repeat Head CT



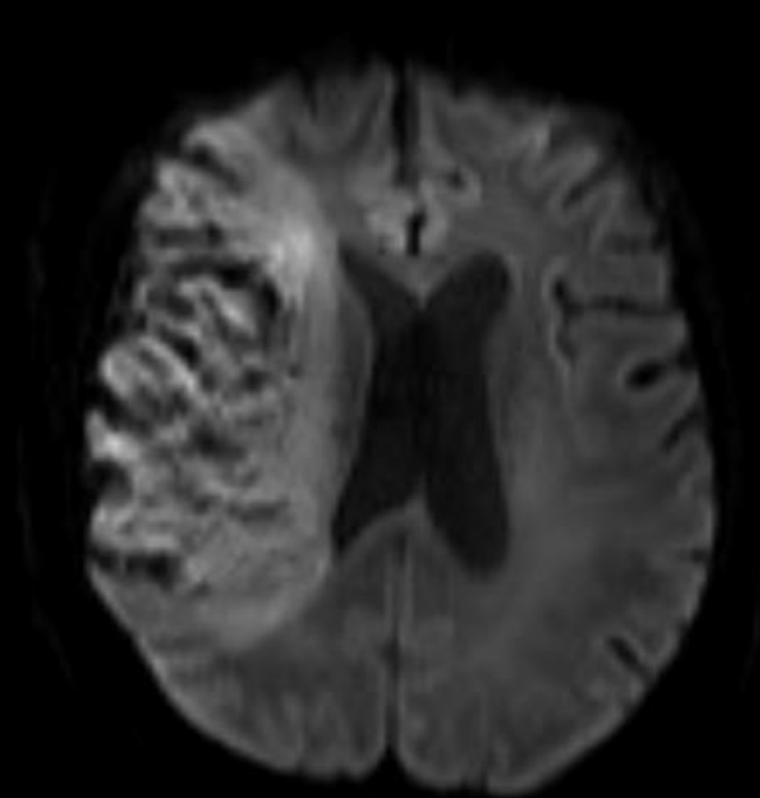
Progression of hemorrhage? Leaky BBB after contrast load?



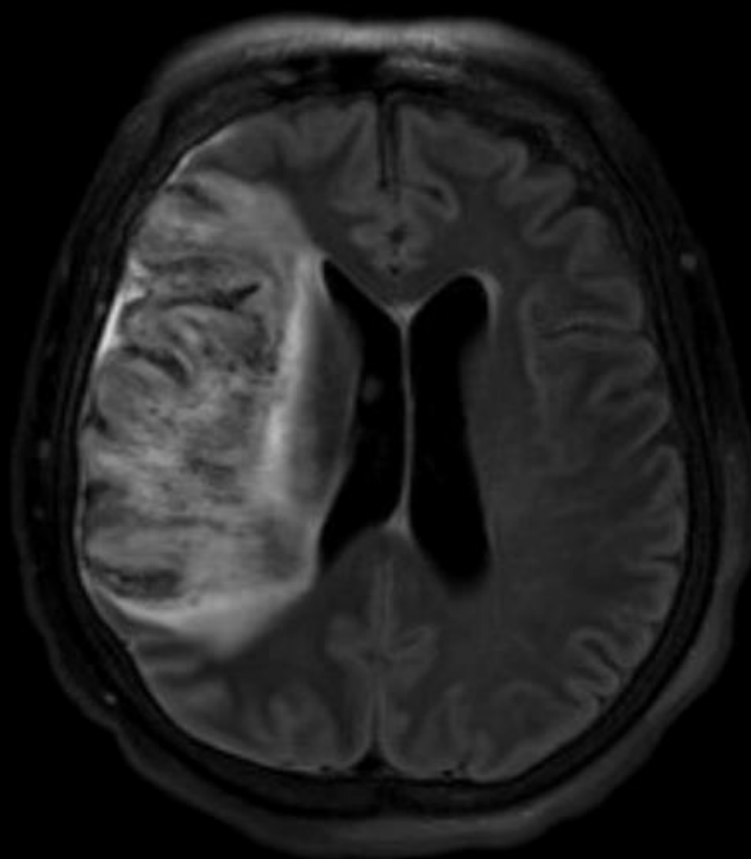
MASSACHUSETTS
GENERAL HOSPITAL

FIREMAN VASCULAR CENTER

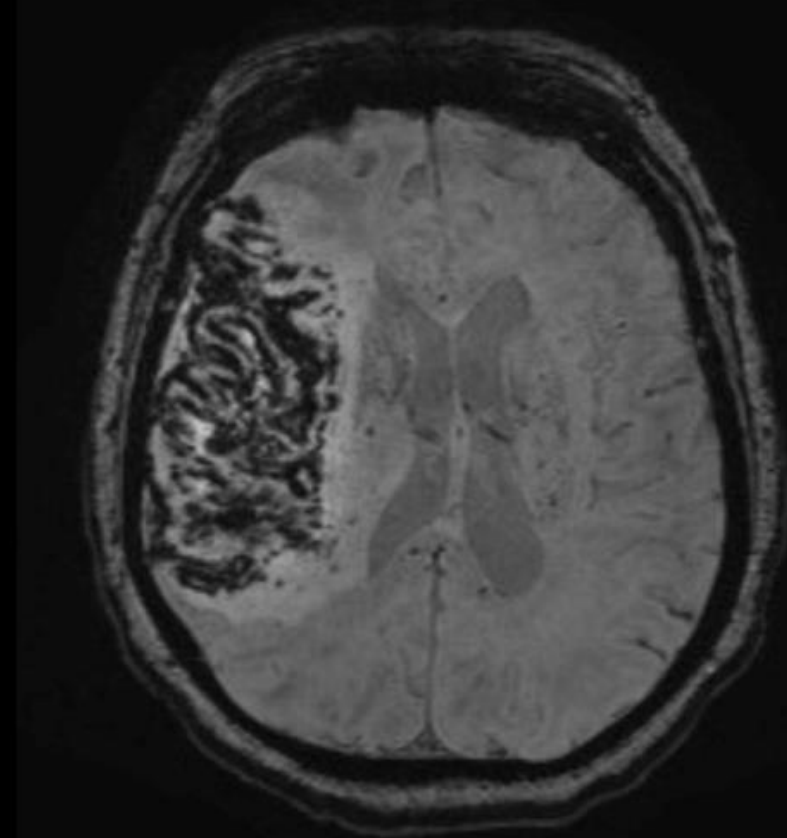
MRI At Receiving Hospital



DWI



FLAIR



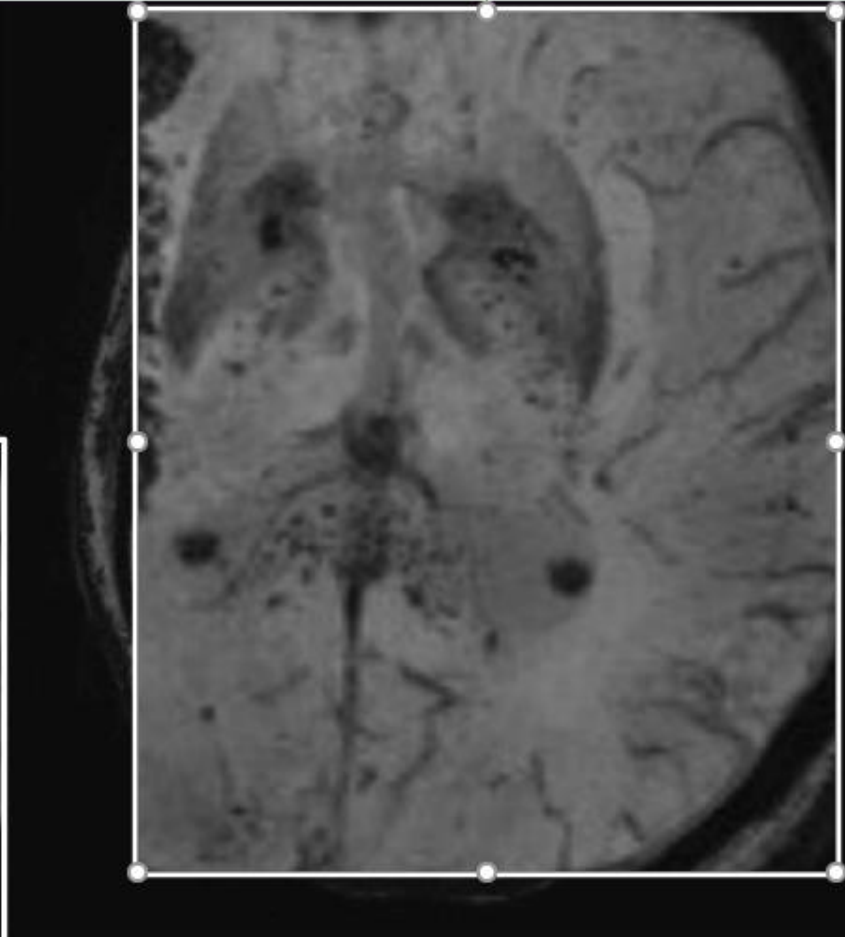
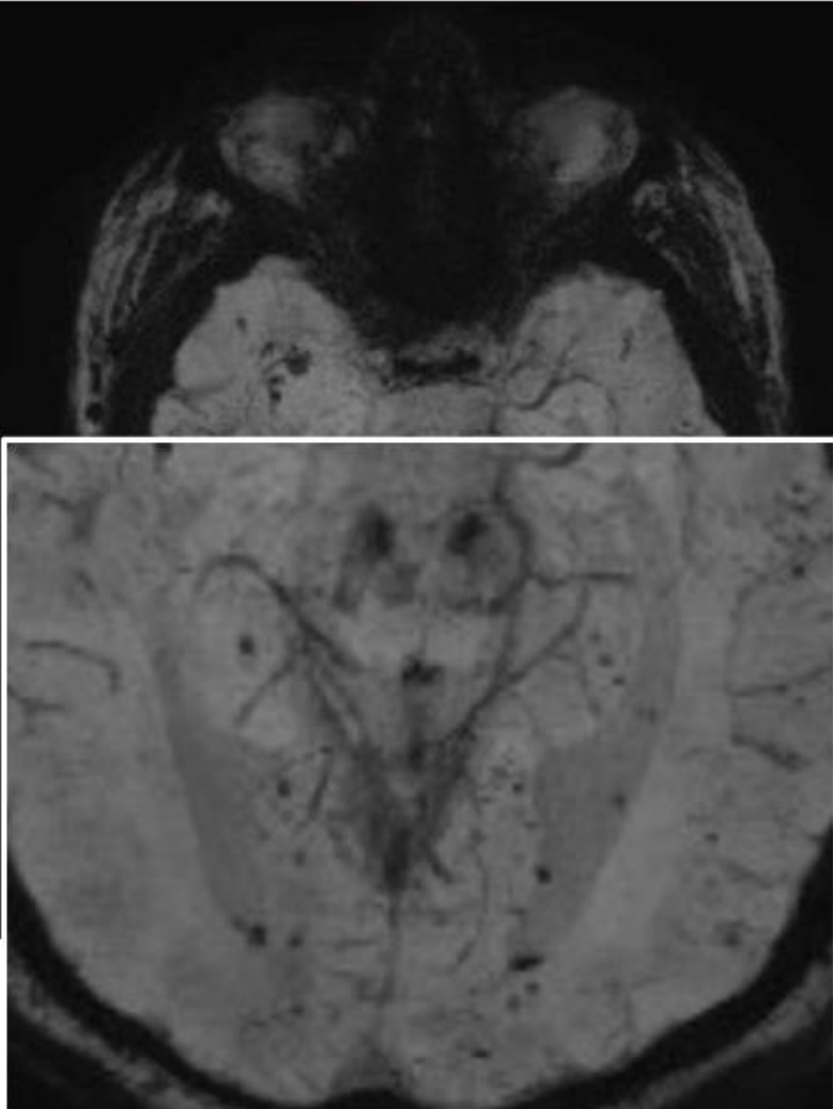
SWI



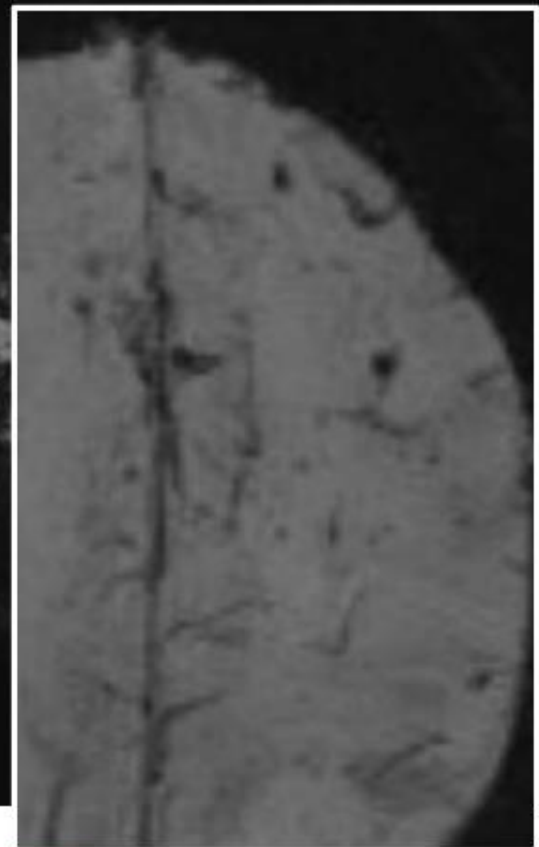
MASSACHUSETTS
GENERAL HOSPITAL

FIREMAN VASCULAR CENTER

Widespread Microbleeds



Prominent lesion burden in the corpus callosum and internal capsules



MASSACHUSETTS
GENERAL HOSPITAL

FIREMAN VASCULAR CENTER

Continued Evaluation

TTE: patent foramen ovale with right to left shunting by agitated saline contrast at rest and with Valsalva maneuver

→ Paradoxical embolus?

COVID-19 nasal swab negative, but SARS-CoV-2 PCR in sputum persistently positive day 27

→ How long are patients infectious/shedding virus?

Hemicraniectomy not required, hypertonics weaned

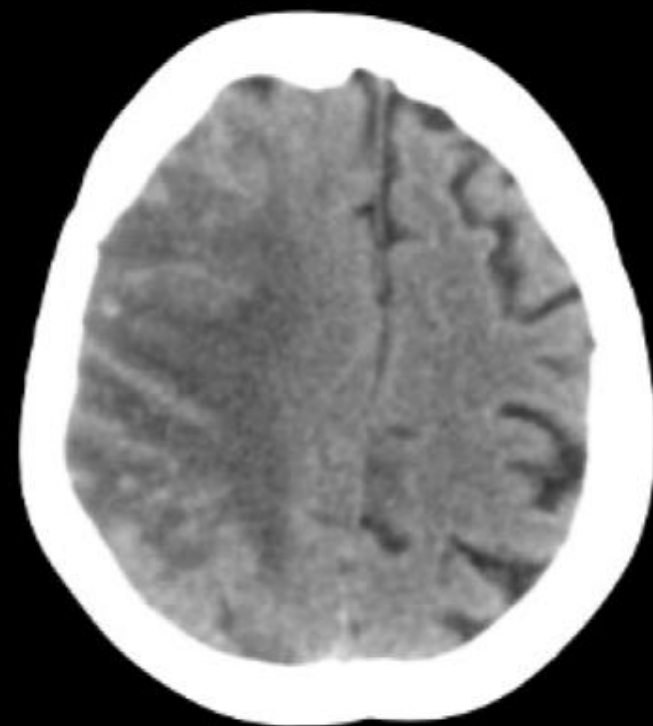
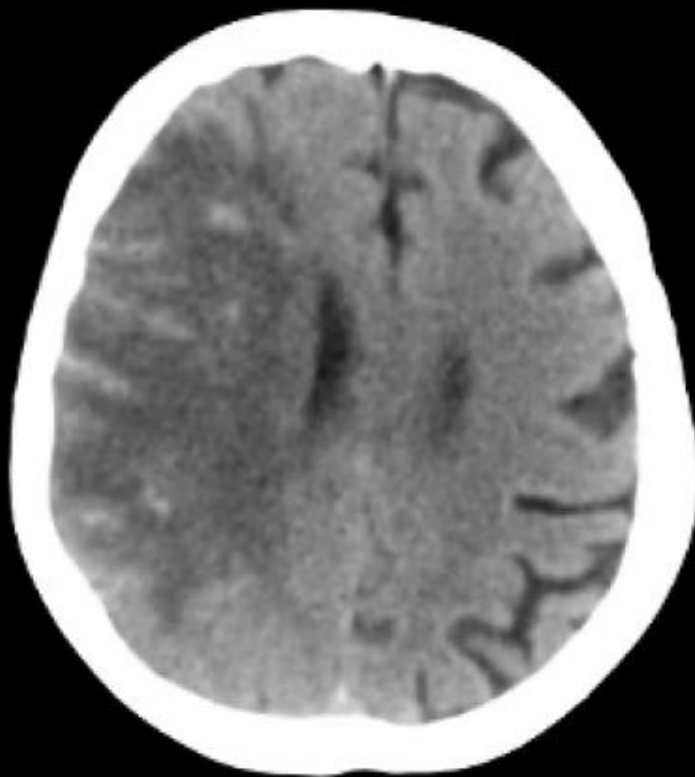
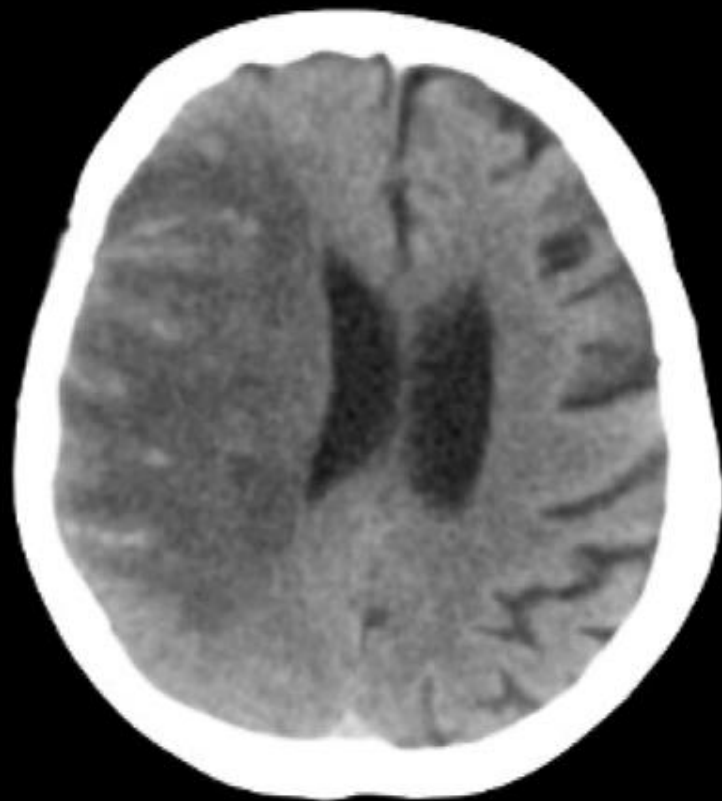
Remained off anticoagulation



MASSACHUSETTS
GENERAL HOSPITAL

FIREMAN VASCULAR CENTER

Repeat Head CT



MASSACHUSETTS
GENERAL HOSPITAL

FIREMAN VASCULAR CENTER

Outcome

- Day 29 patient suffered PEA arrest, unprovoked
- Did not survive code
- Presumed PE since off heparin



MASSACHUSETTS
GENERAL HOSPITAL

FIREMAN VASCULAR CENTER

Discussion Points

- What is the mechanism of diffuse microbleeds?
 - distribution inconsistent with common causes of microhemorrhages (CAA, HTN)
 - has been reported as a rare complication of severe hypoxia (ARDS, high altitude exposure, and ECMO). Is this hypoxia related?
 - May this be a direct viral effect due to endothelial damage?
- How much do this and similar findings contribute to reported encephalopathy in recovering patients?

DR. FESKE- CASE #2

Case: COVID-19 and ICH

30-year-old man with history of polysubstance abuse found down unresponsive without signs of trauma; glu 300.

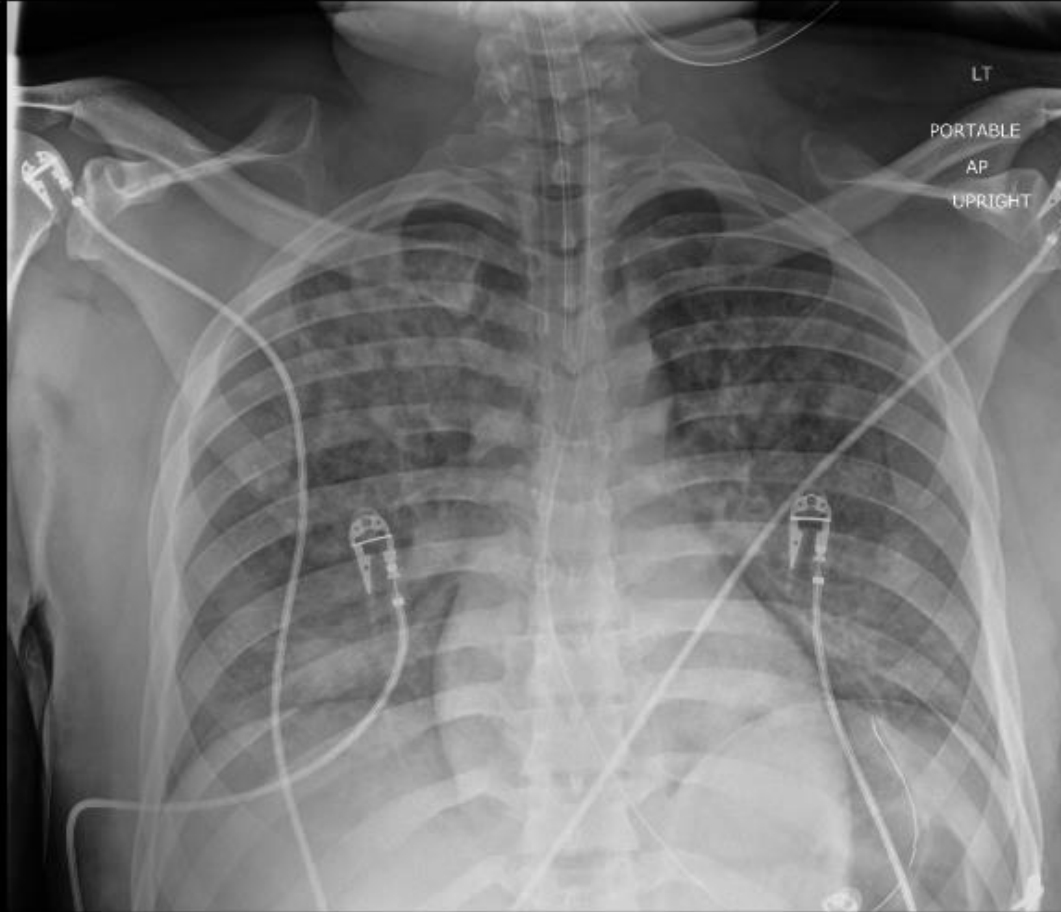
Woke after naloxone to agitated confusion; intubated for persistent hypoxia and increased WOB.

Trauma evaluation, including NCCT was negative.

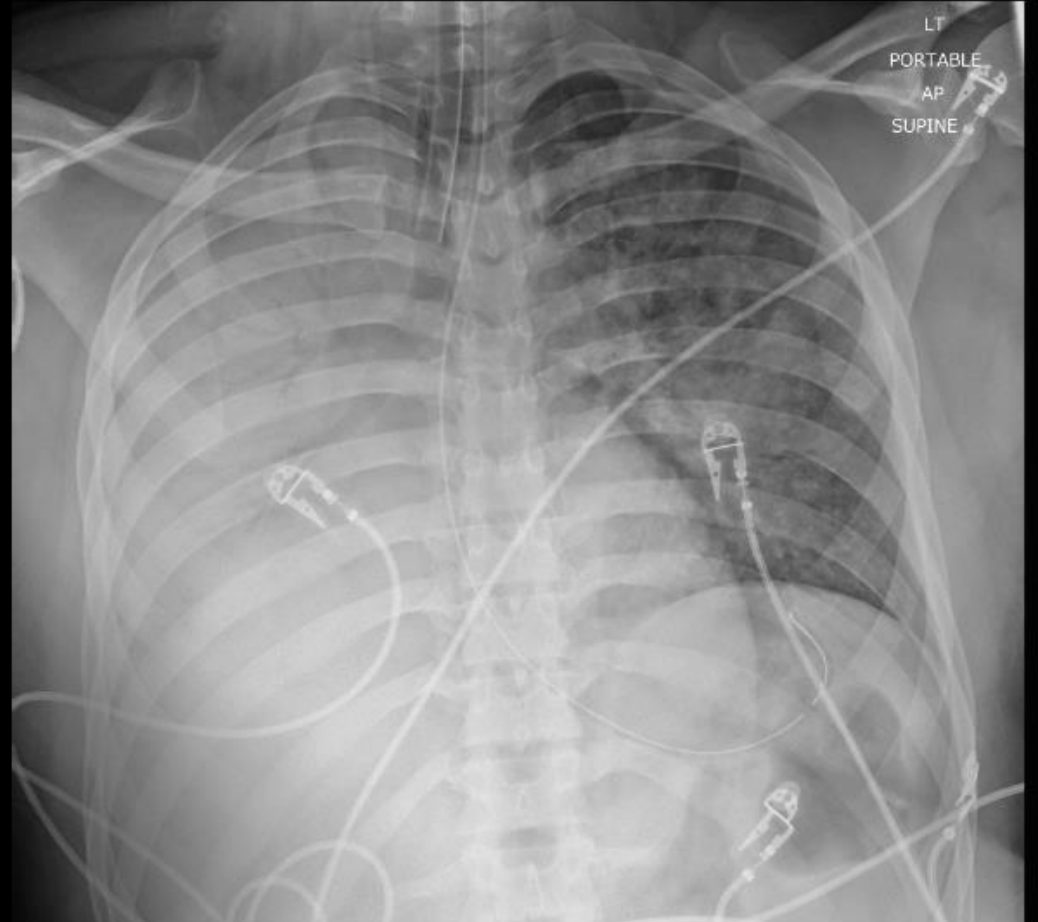
NP swab for SARS-CoV-2 positive; severe bilateral pneumonia requiring proning and consideration of ECMO, although he ultimately improved without ECMO.

Course complicated by aspiration pneumonia, sepsis with metabolic acidosis, thrombocytopenia (63K), left IJ DVT.

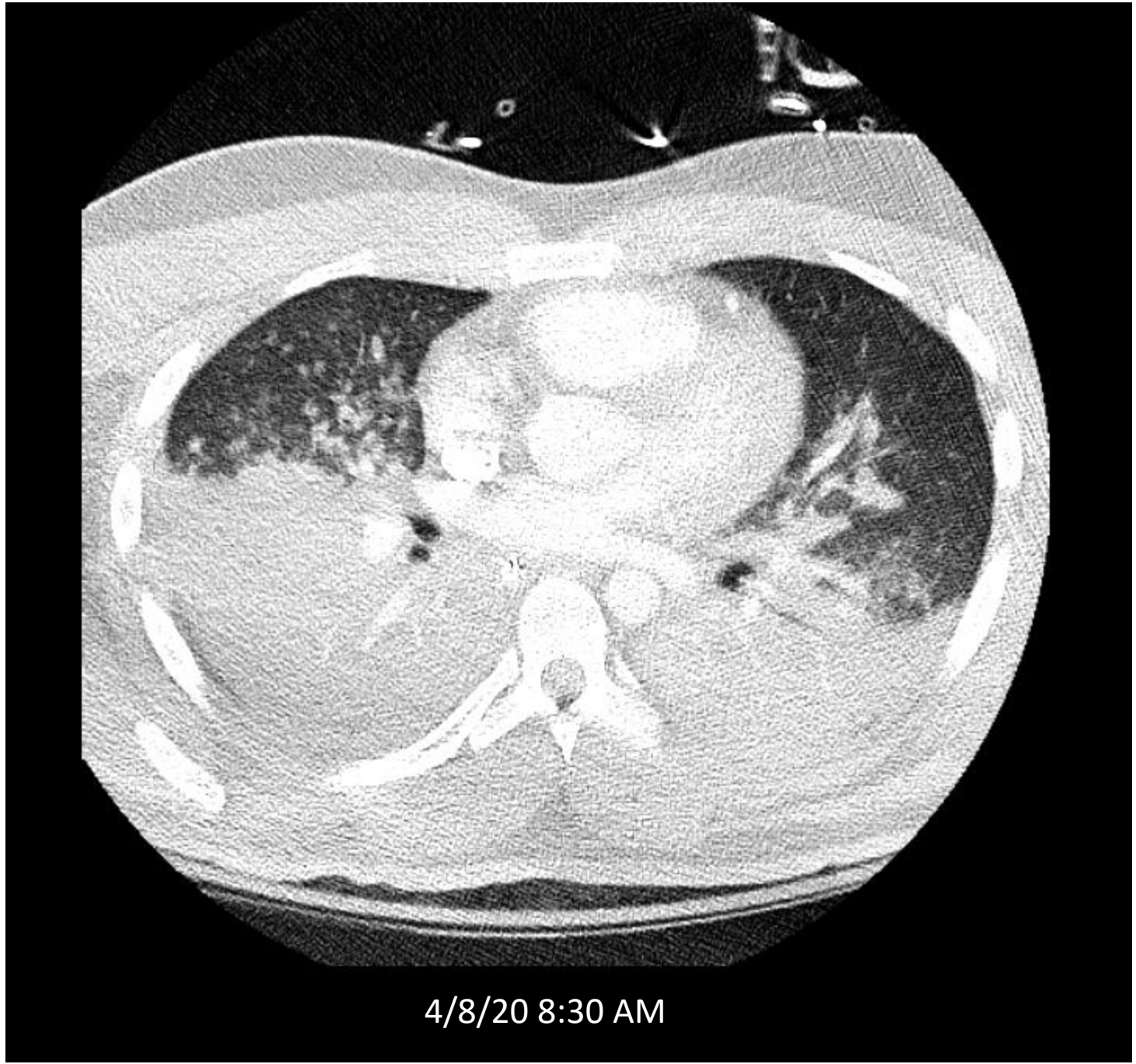
DRVVT confirmed positive; lupus anticoagulant and anti-cardiolipin and anti- β -2- glycoprotein negative.



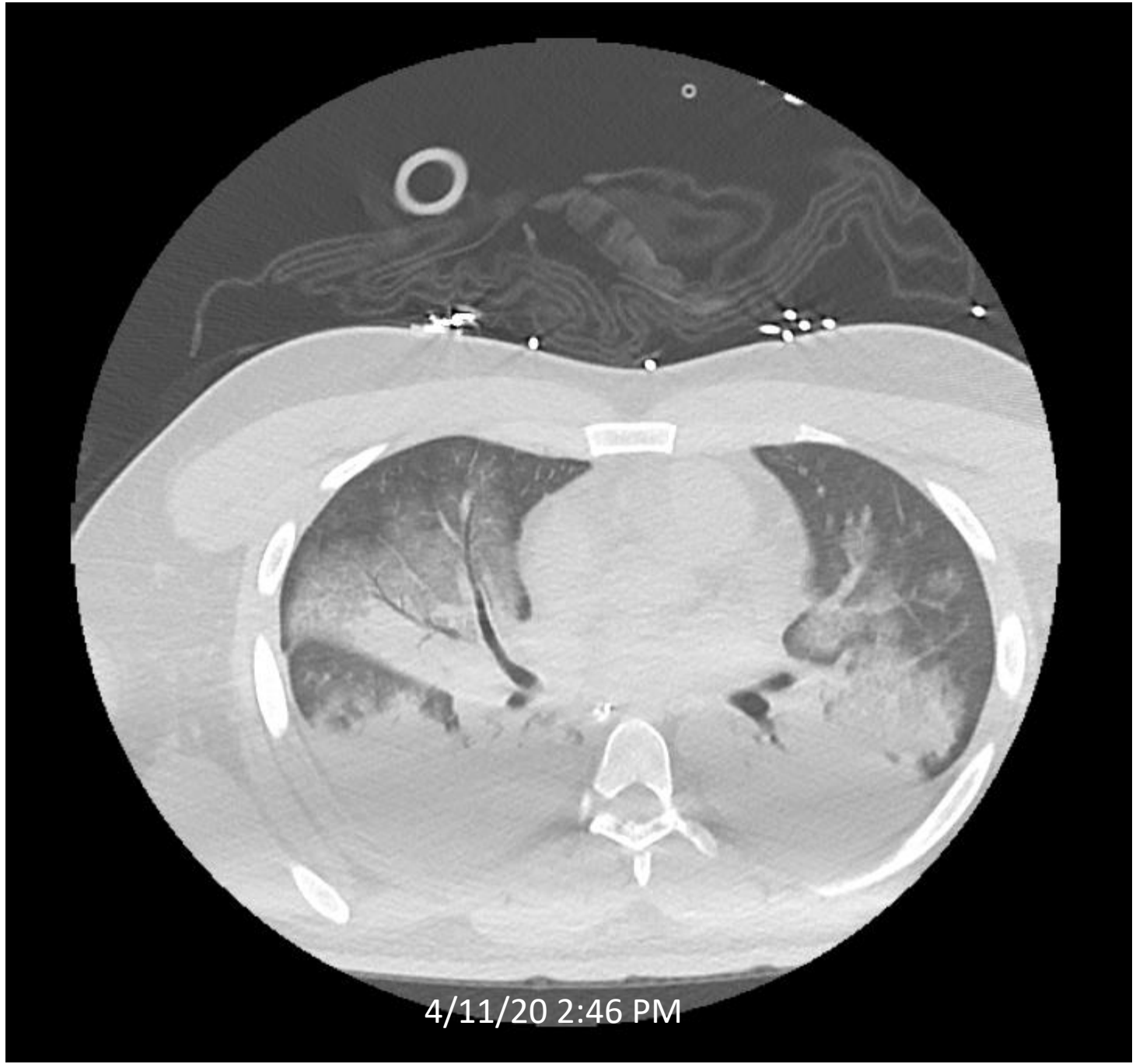
4/8/20 5:42 AM

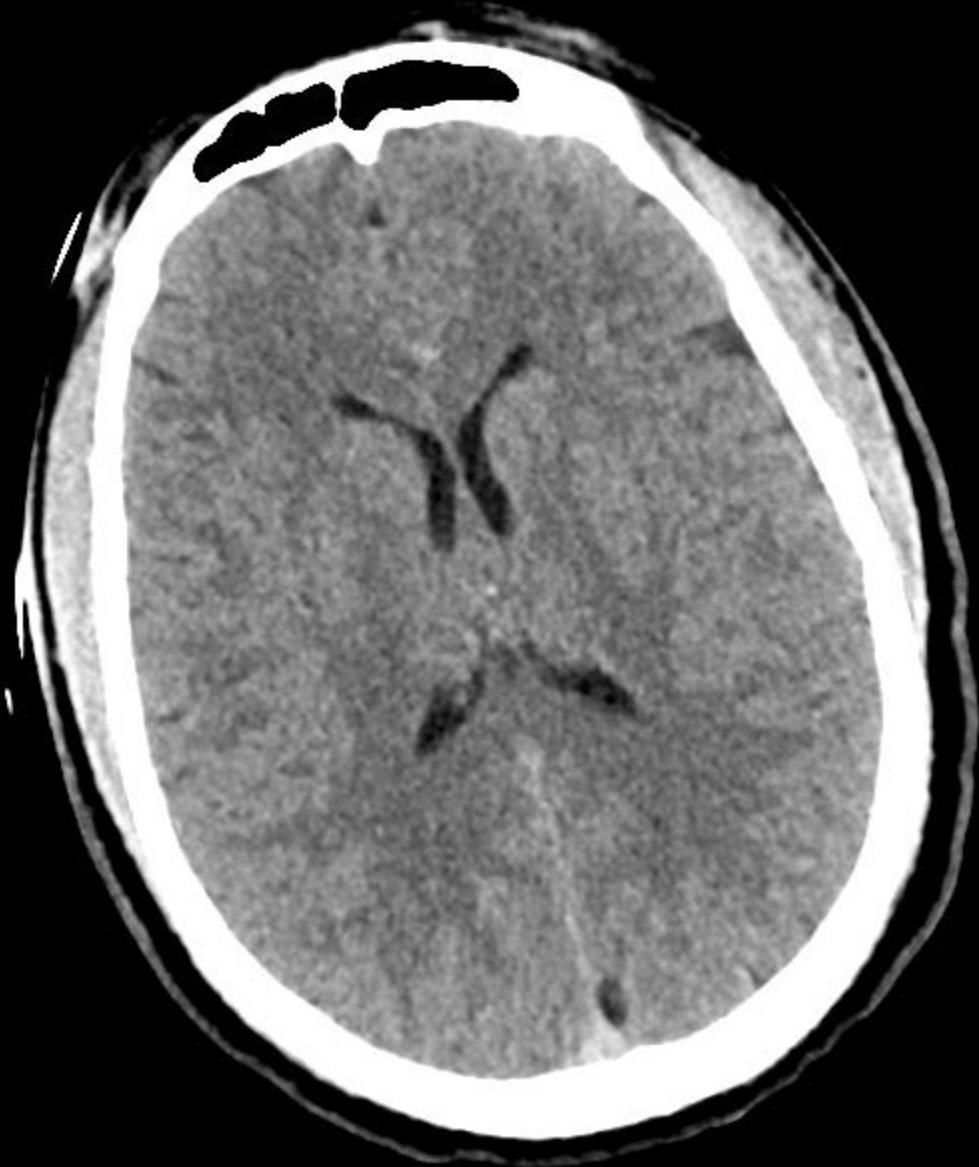


4/8/20 6:58 AM



4/8/20 8:30 AM





NC

Case: COVID-19 and ICH

30-year-old man with history of polysubstance abuse found down unresponsive without signs of trauma; glu 300.

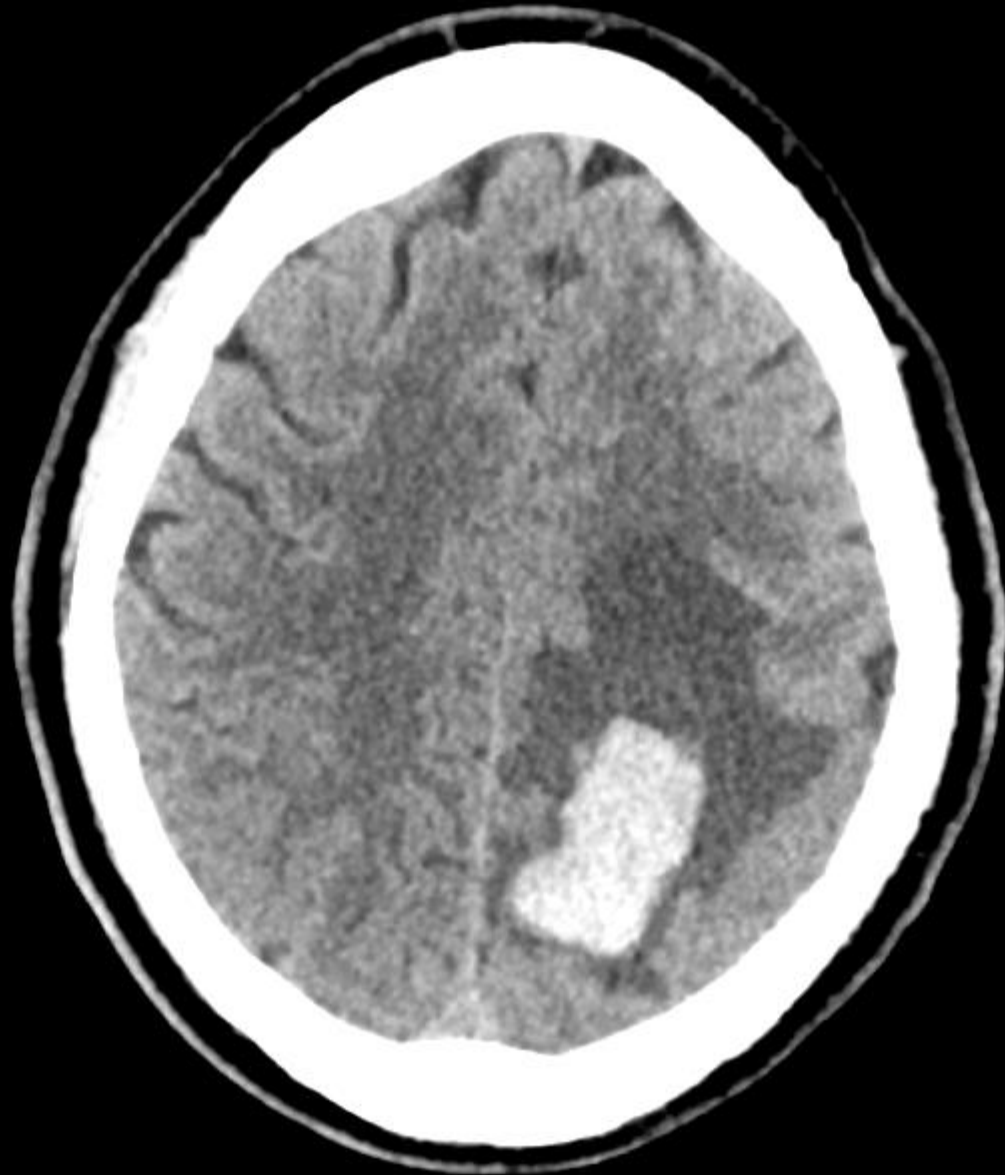
Woke after naloxone to agitated confusion; intubated for persistent hypoxia and increased WOB.

NP swab for SARS-CoV-2 positive; severe bilateral pneumonia requiring proning and consideration of ECMO.

Course complicated by aspiration pneumonia, sepsis with metabolic acidosis, thrombocytopenia (63K), left IJ DVT.

DRVVT confirmed positive; lupus anticoagulant and anti-cardiolipin and anti- β -2- glycoprotein negative.

He was anticoagulated with UFH and then LMWH for the DVT when he developed right arm and leg weakness.



4/24/20 11:14 PM

Case: COVID-19 and ICH

30-year-old man with history of polysubstance abuse found down unresponsive without signs of trauma; glu 300.

Woke after naloxone to agitated confusion; intubated for persistent hypoxia and increased WOB.

NP swab for SARS-CoV-2 positive; severe bilateral pneumonia requiring proning and consideration of ECMO.

Course complicated by aspiration pneumonia, sepsis with metabolic acidosis, thrombocytopenia (63K), left IJ DVT.

DRVVT positive; other test for APLS negative: LA, aCL IgG and IgM, anti- β -2- glycoprotein.

He was anticoagulated with UFH and then LMWH for the DVT when he developed right arm and leg weakness.

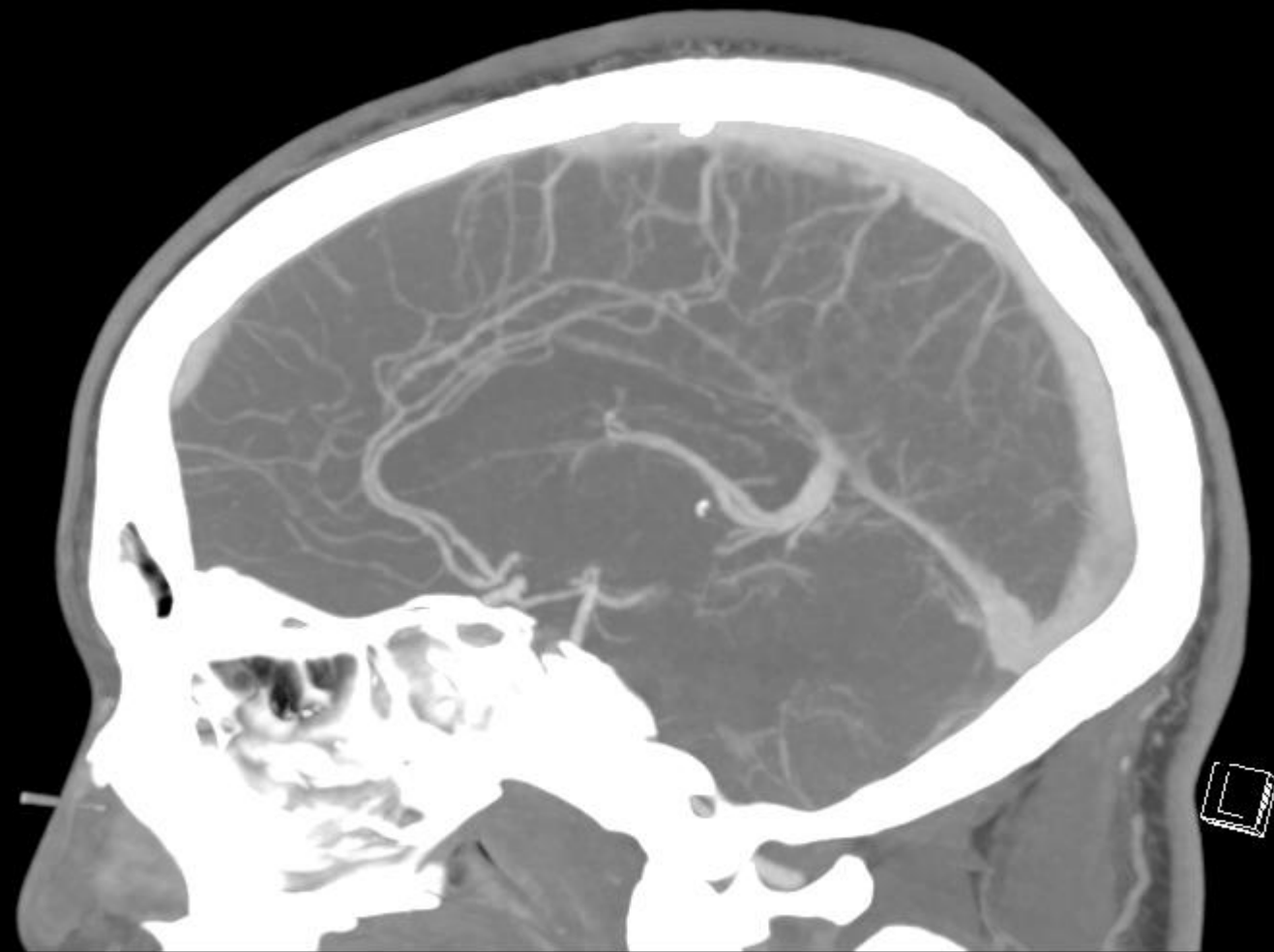
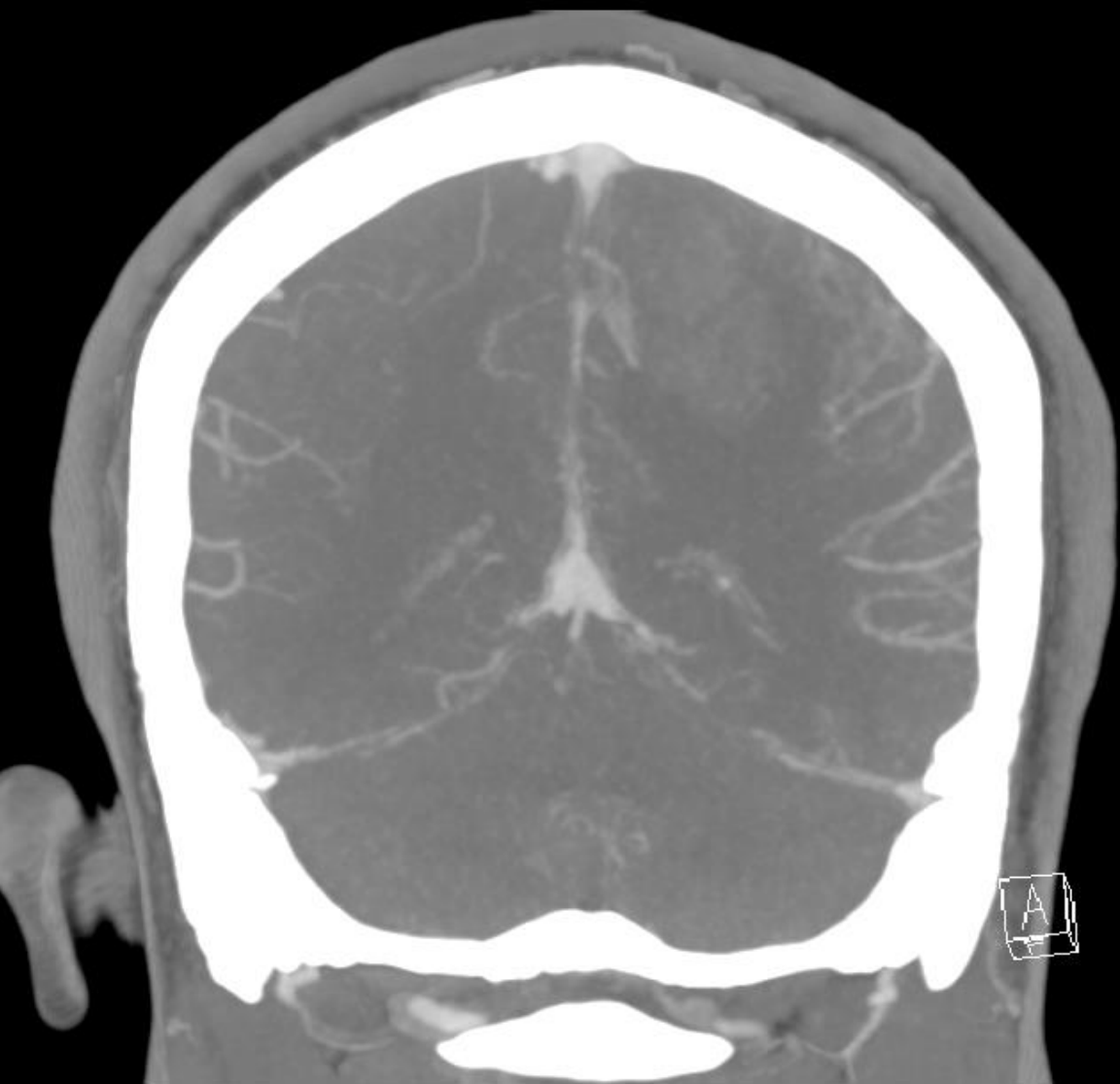Admission urine toxic screen: positive for cocaine and fentanyl

Platelets: 63K 10 days before the CT, but 425K at the time of the CT

PTT elevated to 94 sec 5 days before the CT, 55 sec at the time of the CT; corrected with protamine SO₄.

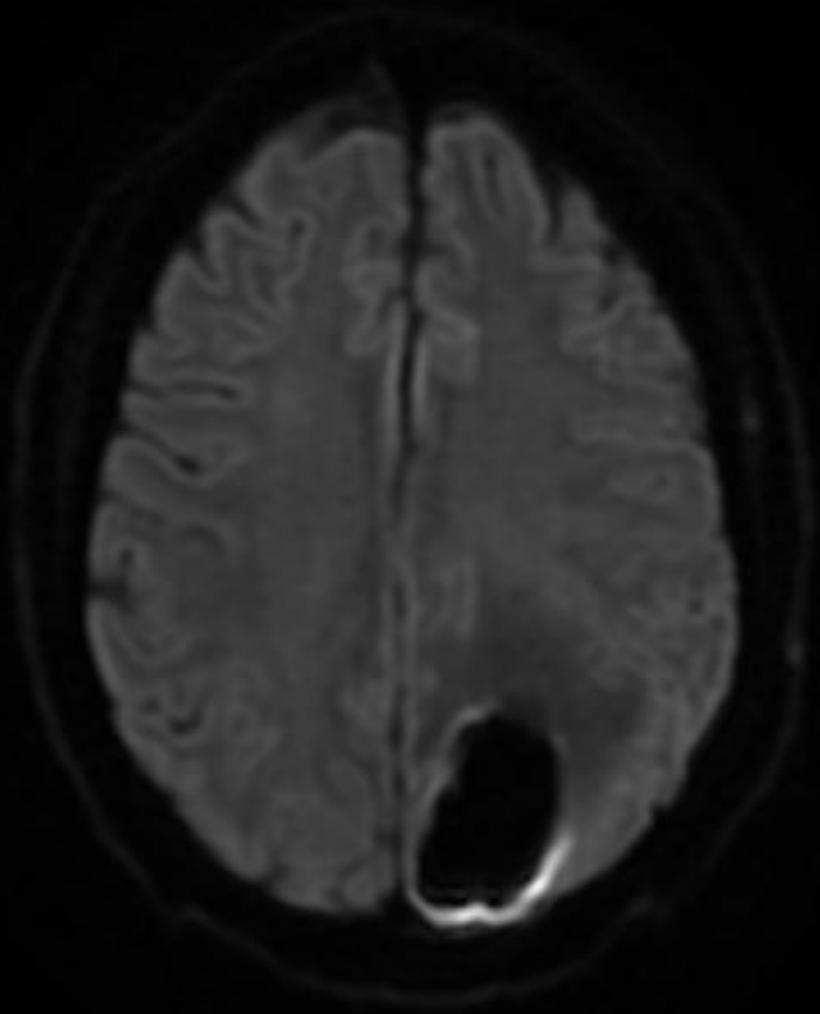
WBC, INR, fibrinogen 464, D-dimer 3308, vWF Ag elevated.

DRVVT positive; other test for APLS negative: LA, aCL IgG and IgM, anti- β -2- glycoprotein.

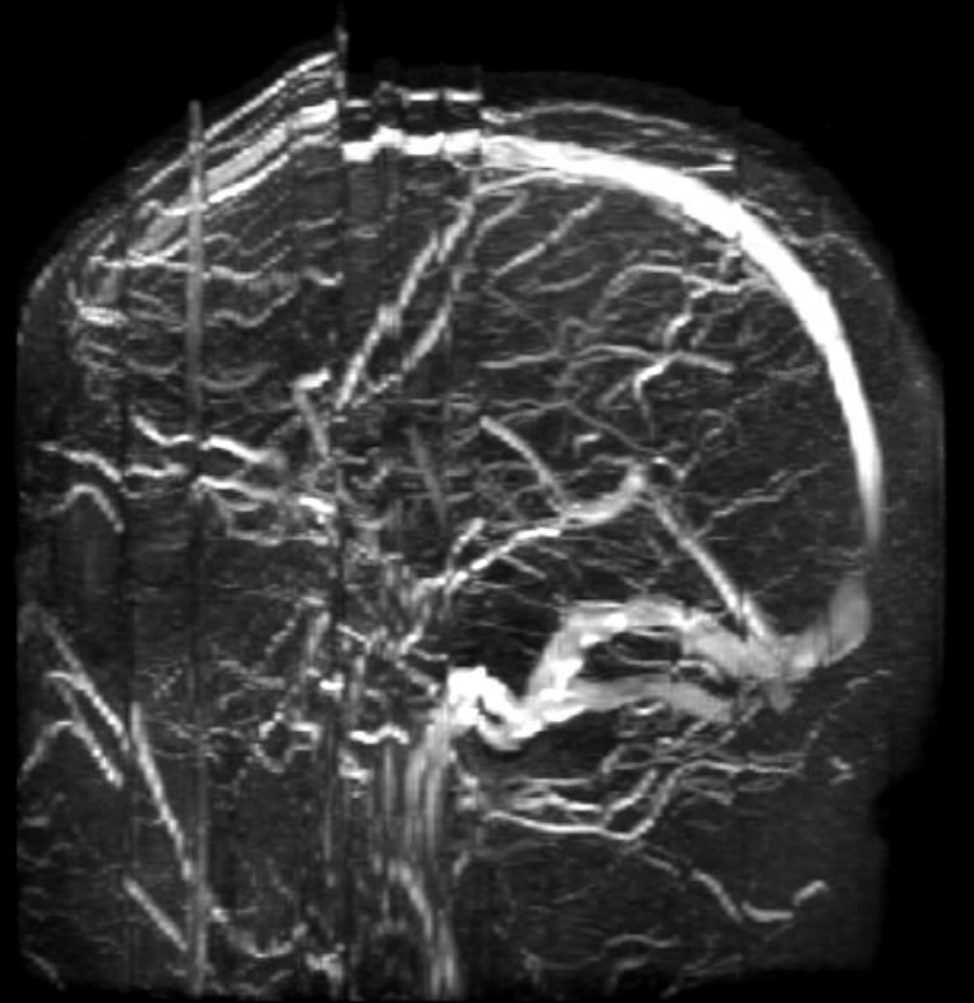


4/24/20 11:14 PM

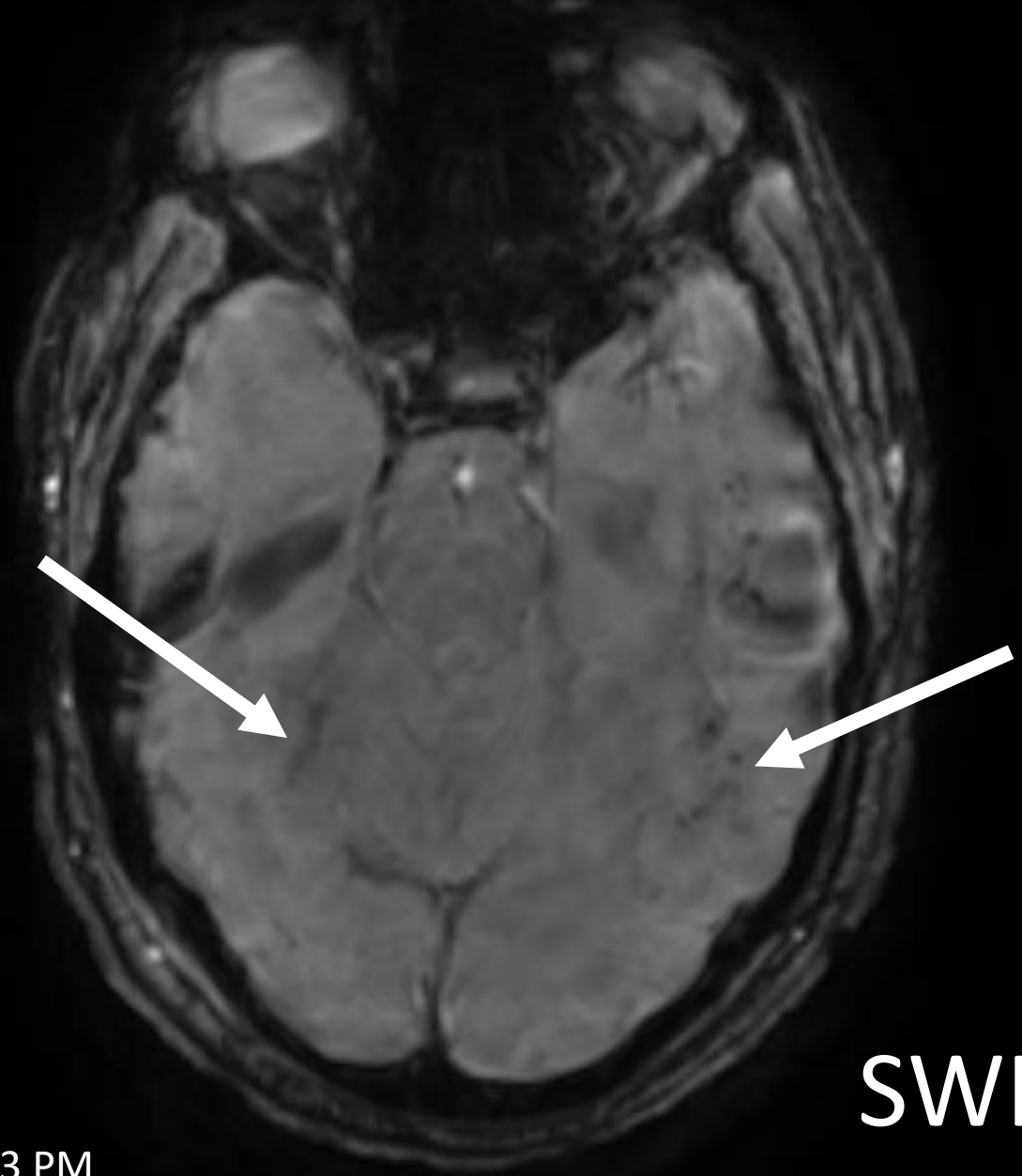
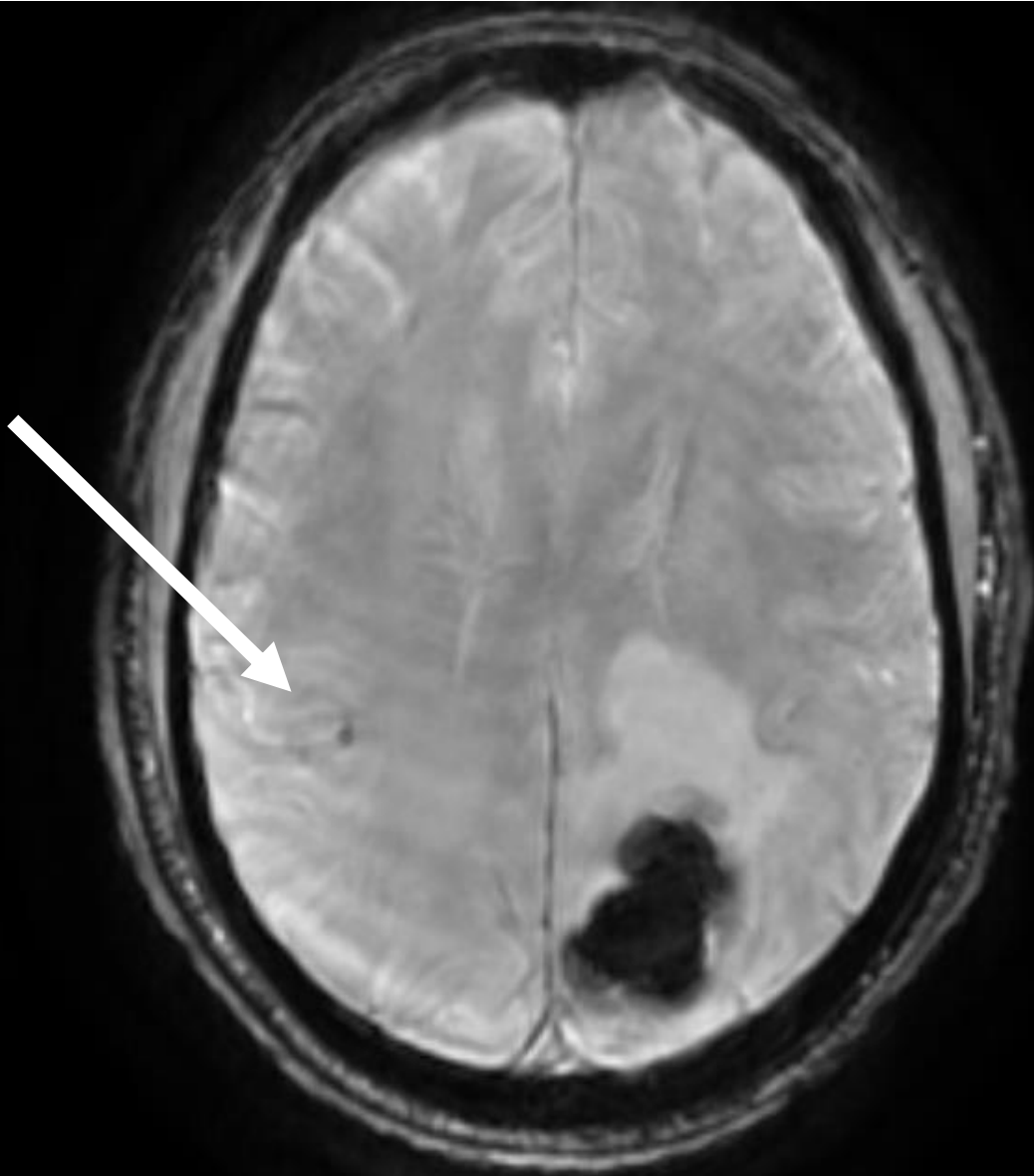
CTA



DWI

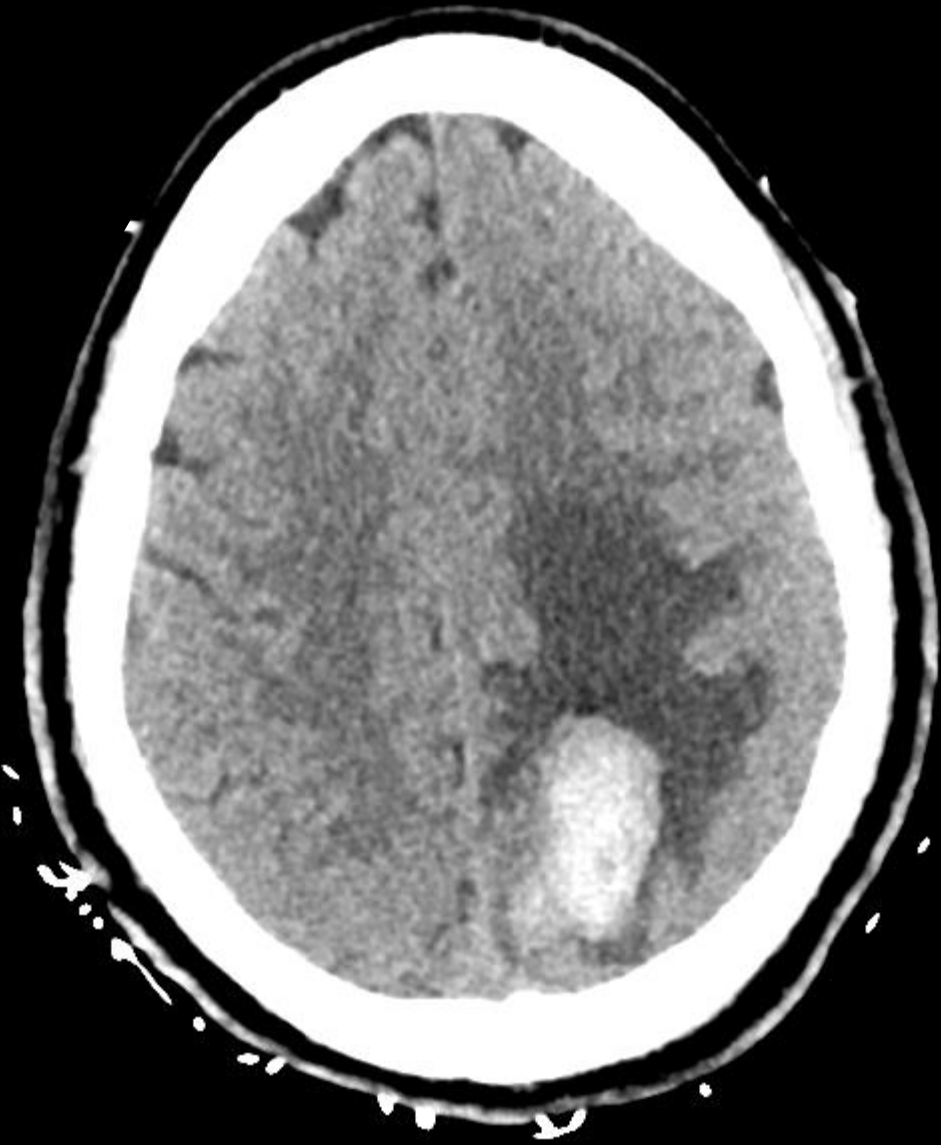

MRV



SWI

4/25/20 2:53 PM



4/30/20 1:40 PM

Considerations

Are patients hypercoagulable? What are the possible mechanisms? Did this patient have APLS? What is the best approach to treatment?

What are the possible causes of cerebral hemorrhage in COVID-19?

What was the likely cause in this case? Should COVID-19 influence the treatment?

What the causes of seizures in COVID-19 patients. Of encephalopathy?

CUCCHIAR-CASE 2

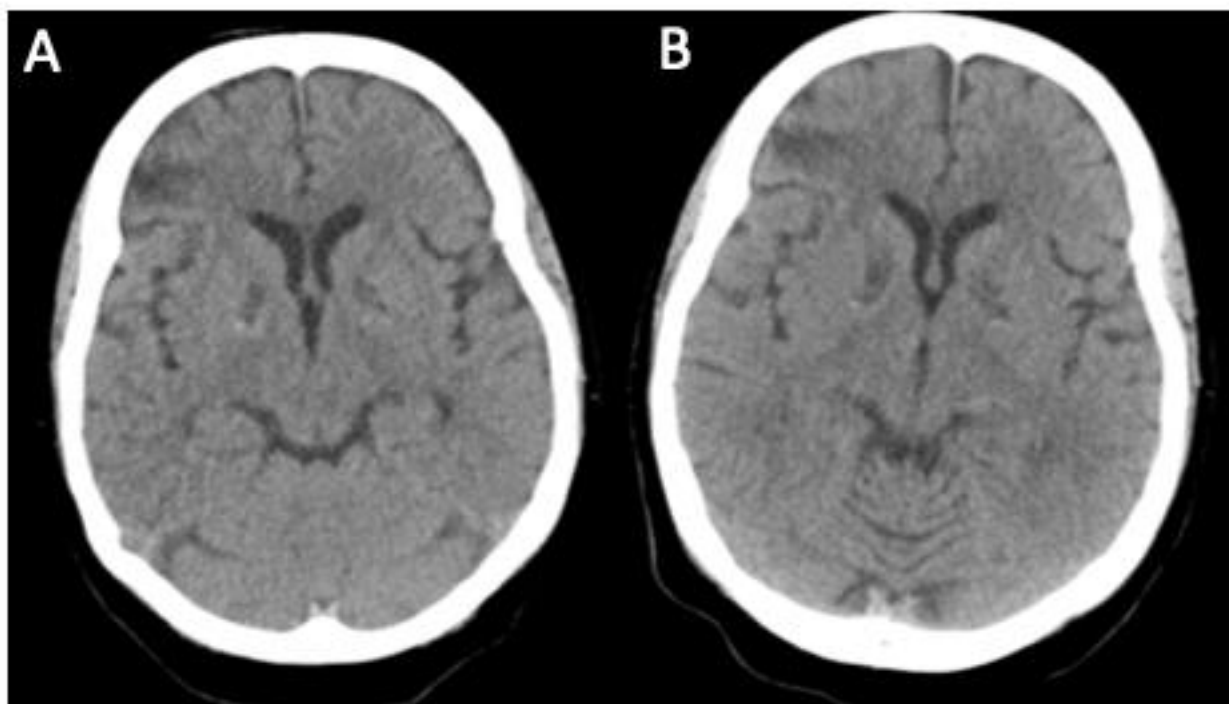
52 YO F WITH HTN AND NEWLY DIAGNOSED, POORLY CONTROLLED DM2 (HEMOGLOBIN A1C OF 17.4)

DEVELOPED BILATERAL HAND PARESTHESIAS THE WEEK PRIOR TO PRESENTATION, FOLLOWED BY DYSPNEA, COUGH, HEADACHE AND CONFUSION.

SHE WALKED IN TO THE ED AFEBRILE, TACHYCARDIC (115 BEATS PER MINUTE), HYPERTENSIVE (220/118 MMHG), AND HYPOXEMIC (OXYGEN SATURATION 49% ON ROOM AIR). SHE HAD NO FOCAL NEUROLOGICAL DEFICITS ON EXAMINATION.

RAPIDLY DEVELOPED REFRACTORY HYPOXEMIA DESPITE 20 LITERS PER MINUTE OF SUPPLEMENTAL OXYGEN AND WAS INTUBATED; COVID PCR+ ON NASAL SWAB

HEAD CT DONE WITHIN 24 HOURS OF ADMISSION



CUCCHIAR-CASE 2

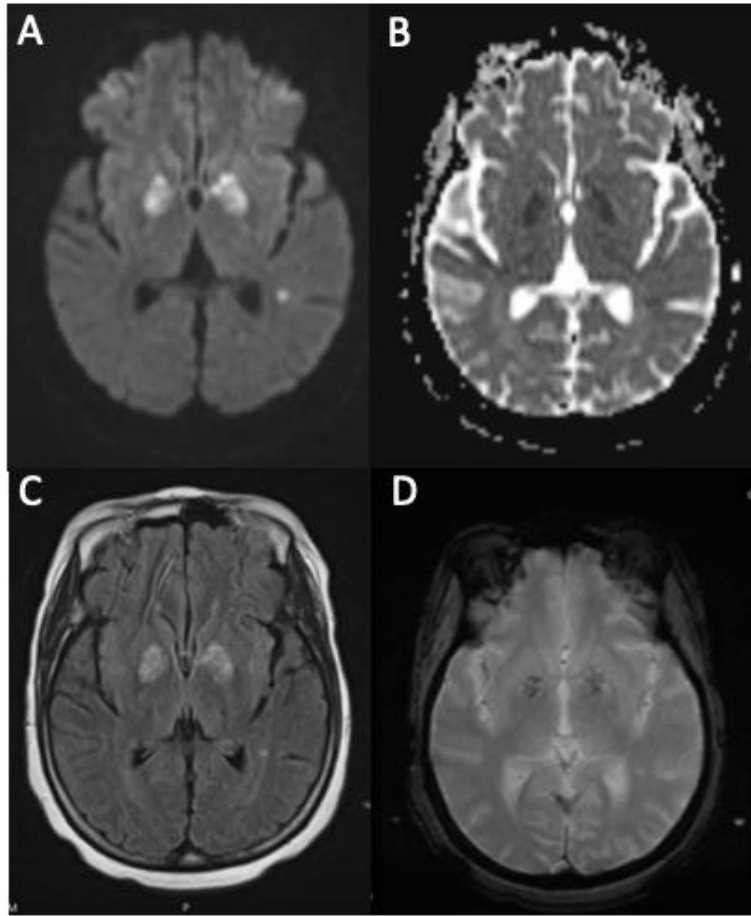
CARBOXYHEMOGLOBIN WAS NOT ELEVATED AND URINE TOXICOLOGY SCREEN WAS NEGATIVE.

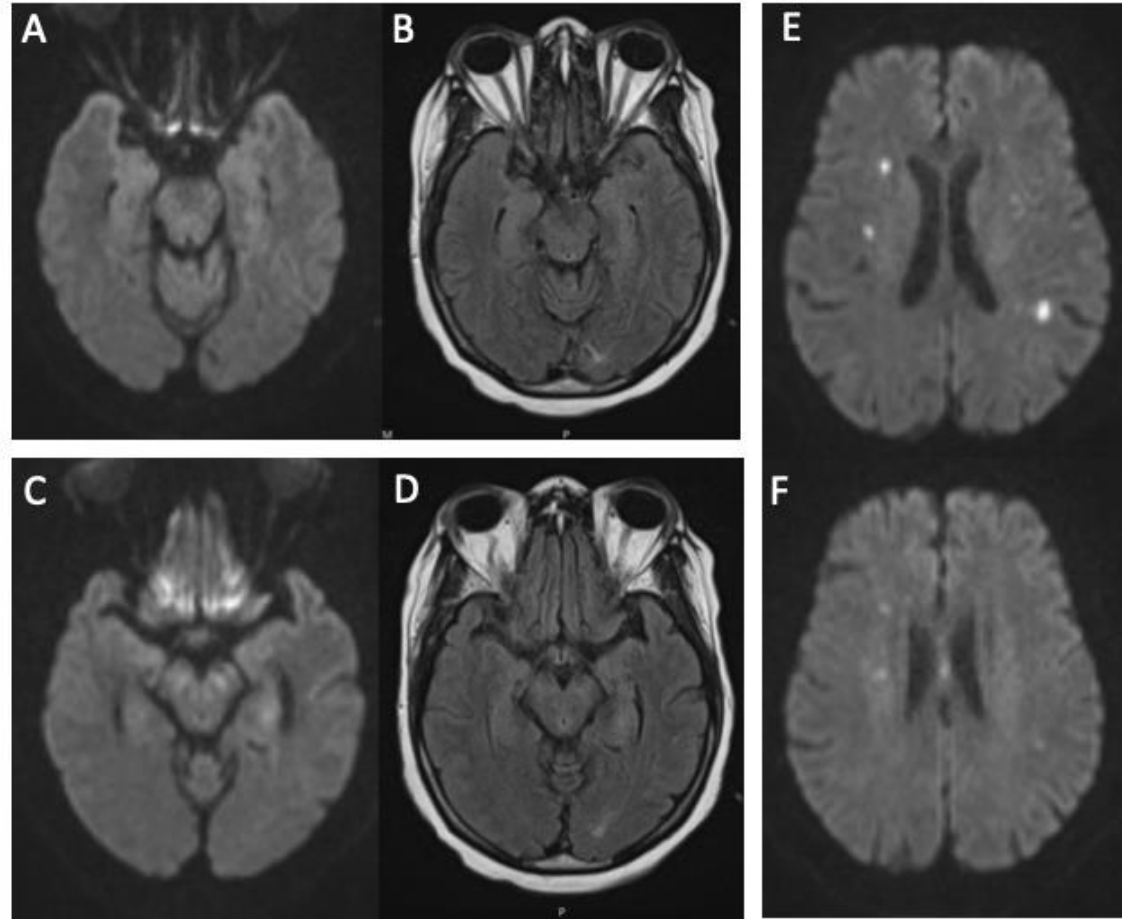
SEVERELY HYPERGLYCEMIC (GLUCOSE 1114 MG/DL) AND SUBSEQUENTLY IN SHOCK WITH LACTATE OF 7.7 MMOL/L, LOW CENTRAL VENOUS SATURATION (52%), AND ELEVATED TROPONIN AND NT-PROBNP. ULTRASOUND SHOWED SIGNS OF RIGHT VENTRICULAR FAILURE AND A SUBCLAVIAN VEIN THROMBUS, AND SHE WAS DIAGNOSED WITH OBSTRUCTIVE SHOCK DUE TO PRESUMED PULMONARY EMBOLISM.

ELEVATED D-DIMER (>128 UG/ML FIBRINOGEN EQUIVALENT UNITS, NORMAL <0.5), LOW FIBRINOGEN (NADIR OF 66 MG/DL), AND LOW PLATELETS (52 THOUSAND CELLS/UL).

SHE WAS STARTED ON A HEPARIN INFUSION, AND REPEAT HEAD CT ON HOSPITAL DAY 3 WAS STABLE. HER COURSE WAS COMPLICATED BY ACUTE RENAL FAILURE REQUIRING CONTINUOUS RENAL REPLACEMENT THERAPY, SHOCK LIVER, AND VENTILATOR-ASSOCIATED PNEUMONIA.

HER MENTAL STATUS REMAINED POOR ON HOSPITAL DAY 8. THEREFORE, A BRAIN MRI WAS OBTAINED





CUCCHIAR-CASE 2

IMAGING C/W BILATERAL GLOBUS PALLIDUS INFARCTIONS; SIMILAR INFARCTION PATTERN REPORTED IN PATIENTS WITH CARDIAC ARREST/SEVERE HYPOXIC-ISCHEMIC INJURY, OFTEN DUE TO DRUG OVERDOSE

MULTIFOCAL OTHER STROKES WITH POSSIBLE IBZ WATERSHED TOPOGRAPHY

CUCCHIAR- CASE 2

WHAT IS THIS?

HYPOXIA OUT OF PROPORTION TO CLINICAL SYMPTOMS
RECOGNIZED IN COVID-19

SEVERE COAGULOPATHY COMMON IN CRITICALLY ILL COVID
PATIENTS

METABOLIC DERANGEMENT WITH HYPERGLYCEMIA MAY HAVE
INCREASED VULNERABILITY TO INJURY (MR PATTERN NOT TYPICAL OF
HYPERGLYCEMIC INJURY THOUGH)



American Heart Association®

COVID-19 CVD Registry™

Powered by Get With The Guidelines®



GETTING STARTED, WHAT YOUR HOSPITAL NEEDS TO KNOW

Please email the following information to qualityresearch@heart.org using the subject line, “[your hospital’s name] interest in COVID-19 CVD Registry Participation”

- Hospital name and location
- Which Get With The Guidelines® (GWTG) modules hospital currently participates in, and GWTG Site ID if known
- Name and email of person leading the contracting
- Name and email of lead physician champion for the registry
- Do you have an onsite clinical chemistry laboratory? If yes, please describe its capacity for running serial standard blood tests.

Once received, AHA staff will review and contact you with any questions.

The website is:

www.heart.org/covidregistry



[+ Heart Attack And Stroke Symptoms](#)[👤 Volunteer](#)[🛒 SHOP](#)[❤️ Donate Now](#)[Healthy Living ▾](#)[Health Topics ▾](#)[Professionals ▾](#)[Get Involved ▾](#)[Ways to Give ▾](#)[About Us ▾](#)[CPR ▾](#)[Find Your Local Office ▾](#)

[Home](#) / [Professional Resources](#) / [Quality Improvement](#) / **COVID 19 CVD Registry**

COVID-19 CVD Registry

To better understand the COVID-19 pandemic, the American Heart Association has developed a new registry for hospitals and health systems caring for COVID-19 patients.

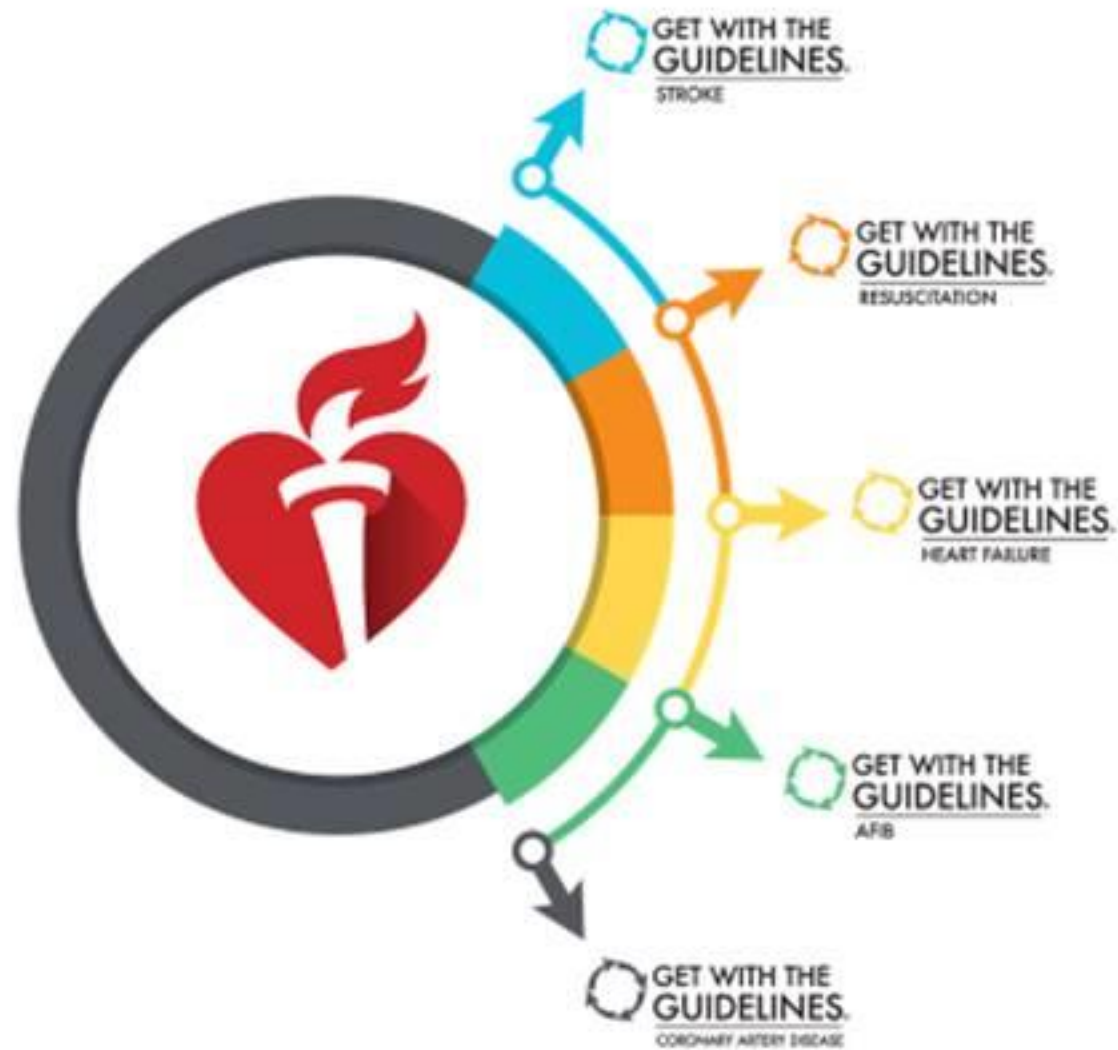

WHAT WE NEED FROM YOU

- Please review the website www.heart.org/covidregistry
- Streamlined enrollment:
 - Abbreviated amendment for existing customers
 - Accelerated web-based contracting for new customers
- Email any questions to Qualityresearch@heart.org using the subject line, “[your hospital’s name] interest in COVID-19 CVD Registry Participation”



QUALITY IMPROVEMENT PROGRAMS



MISSION:
LIFELINE

TARGET:
PROGRAMS

HOSPITAL
Accreditation
& Certification

<https://www.heart.org/en/professional/quality-improvement>



STROKE AND DIABETES

NEXT
WEBINAR!



May 27th
11am CST

Missy Moreda MSN APRN ACCNS-AG CCRN CNRN SCRNP, will be presenting. Missy has more than 20 years of experience as a neuro ICU nurse and is currently a Diabetes Educator Clinical Nurse Specialist for Duke Raleigh Hospital.



life is why[™]
es por la vida[™] 全為生命[™]